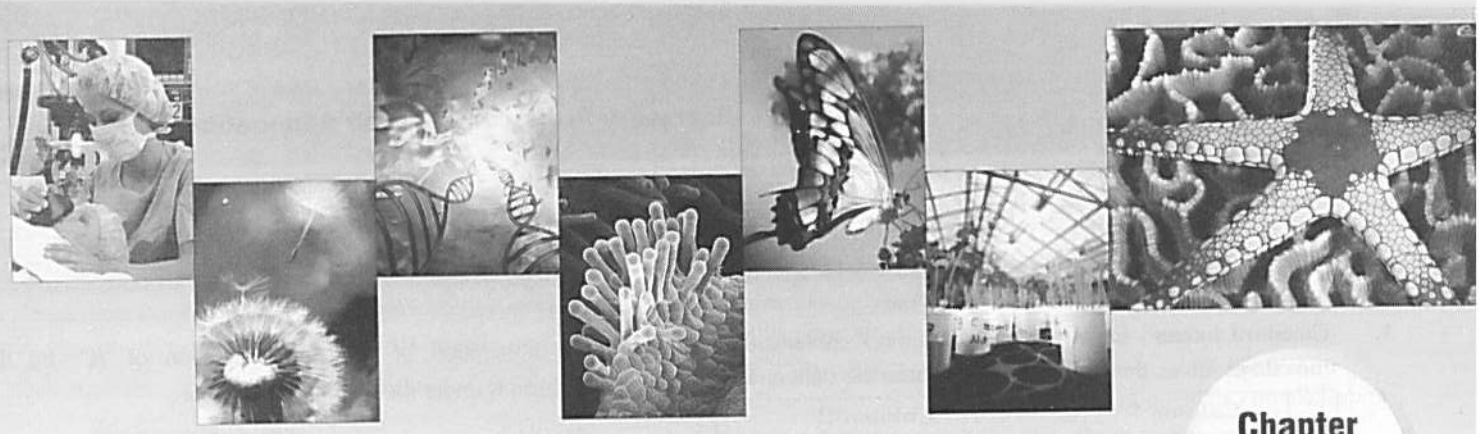

Chapter

5.5

Locomotion and Movement

The study of bone structure and treatment of bone disorders is called osteology. The specialized branch of medicine that deals with preservation and restoration of skeletal system, joints is called orthopedics. Bones are made up of a protein called ossein and cartilage are made of a protein called chondrin. Hence study of bones is called osteology and study of cartilage is called chondrology. Body of animals (vertebrates) is supported by skeleton.

Skeleton

The hardened tissues of the body together form the skeleton (*sclero* = hard). Skeleton of invertebrates is most often secreted on the surface, forming a lifeless or dead exoskeleton. Whereas skeleton of vertebrates develops most often underneath the surface forming a living or growing endoskeleton. Three types of skeletons develop in vertebrates :

(1) **Epidermal/Horny exoskeleton :** These include hard and horny keratinized derivatives of epidermal layer of skin, such as claws, most reptilian's scales, bird feathers and mammalian hairs, horns, nails and hoofs, etc. All living amphibians lack an exoskeleton.

(2) **Dermal/Bony skeleton :** Dermal bony skeleton is derived from the dermis of skin. It includes bony scales and plates or scutes (*osteoderms*), finrays and antlers of fishes, some reptiles (crocodiles, turtles and tortoises) and mammals. In fishes, dermal scales become exposed due to wearing out of epidermis, and form exoskeleton.

(3) **Endoskeleton :** Greater part of vertebrate skeleton lies more deeply, forming the endoskeleton. It develops from mesenchyme. Endoskeleton is formed by bones in vertebrates. Skeleton in different animals are as follows –

Invertebrate –

(i) Protozoa – No skeleton.

(ii) Porifera – Calcareous spicules + silicious spicules + spongin fibre in mesenchyme.

Spicules in porifera represent endoskeleton.

(iii) Coelenterata – Calcareous (corals) and chitinous (perisarc).

(iv) Helminth – No skeleton, cuticle7 present.

(v) Annelida – No skeleton, cuticle present.

In earthworm and ascaris hydrostatic skeleton is found that is fluid is filled in coelom and form turgid skeleton.

(vi) Arthropoda – Dead chitinous exoskeleton, shed at intervals, called ecdysis or moulting. Cuticle made up of non chitinous outer epicuticle and chitinous, inner endocuticle.

(vii) Mollusca – Calcareous shell, may be external or internal or absent.

(viii) Echinodermata – Dermal calcareous plates are present.

(ix) Hemichordates – Endoskeleton in form of proboscis skeleton, pygochord.

In vertebrates exoskeleton may be epidermal or dermal.

Vertebrates : In vertebrates dermal skeleton is formed by bones. Bone is the connective tissue with intercellular spaces filled with ossein matrix composed of 25% water, 25% protein fibers, 50% mineral salts. The inner most region is full of bone marrow having various types of cells. In mammals the bone is full of haversian canals. The bones are of following types –

(i) **Cartilage bones :** The bones which are formed by the ossification of preexisting cartilage are called cartilage bones or replacing bones. *e.g.*, vertebra, Girdles, limb bones, basioccipital, supraoccipital, sphenoid, Incus, malleus, stapes.

(ii) **Membrane or dermal bones :** The bones which are formed by independent ossification in connective tissue are called dermal, membrane or investing bones. *e.g.*, Ribs, sternum, clavicle, Nasal, vomer, palatine, maxilla.

(iii) **Sesamoid bones :** Ossification takes place on ligament *e.g.*, cotyloid bone of Rabbit and tendons *e.g.*, Patella, Pisiform.

(iv) **Pneumatic bones** : Bones with hollow spaces containing air *e.g.*, bones of bird, frontal, sphenoid, ethmoid, maxilla of human.

(v) **Irregular bones** : Vertebrae are irregular bone.

(vi) **Flat bones** : Cranial bone, scapula, Ribs.

(vii) **Short bones** : Carpals and tarsals.

Functions of endoskeleton : Chief function of vertebrate endoskeleton can be enumerated as follows

(i) To provide physical support to body by forming a firm and rigid internal framework.

(ii) To give definite body shape and form.

(iii) To protect delicate internal organs like brain, heart, lungs etc.

(iv) To permit growth of huge body size (whale, elephant, extinct dinosaurs), since it is living and growing.

(v) To provide surface for attachment of muscles.

(vi) To serve as levers on which muscles can act.

(vii) To manufacture blood corpuscles in bone marrow.

(viii) To help in breathing (tracheal rings, ribs).

Endoskeleton of vertebrates

(1) Axial endoskeleton : (Skull + Vertebral column + Sternum + Ribs)

(2) Appendicular endoskeleton : (Girdle + Limb bones)

SKELETON
- Axial skeleton
  - Skull
    1. Cranium
    2. Facial region
    3. Optic capsule
    4. Auditory capsule
    5. Olfactory capsule
    6. Visceral part
  - Vertebral column
    1. Cervical region
    2. Thoracic region
    3. Lumbar region
    4. Sacral region
    5. Caudal region
  - Sternum and Ribs
- Appendicular skeleton
  - Girdles
    1. Pectoral
    2. Pelvic
  - Limb bones
    - Bones of fore limb
      1. Upper arm
      2. Fore arm
      3. Wrist bones
      4. Palm bones
      5. Phalanges
    - Bones of hind limb
      1. Thigh bone
      2. Shank bone
      3. Ankle bone
      4. Foot bones
      5. Phalanges

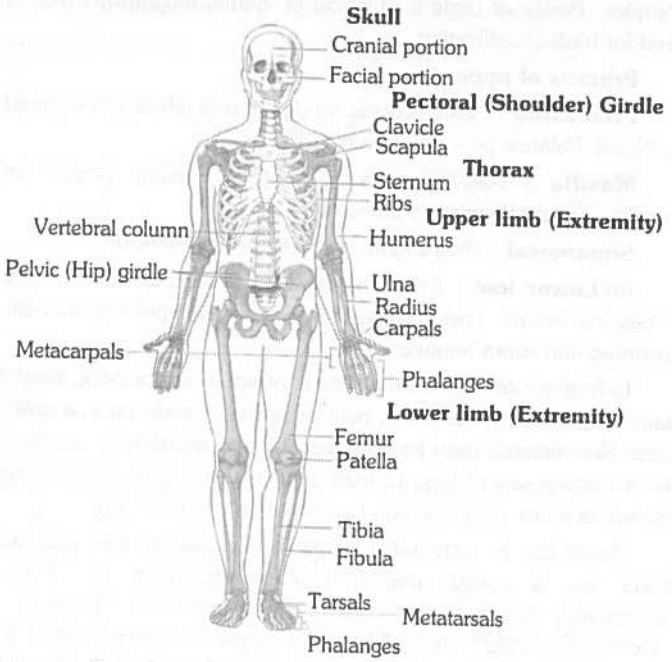

Fig : 5.5-1 Divisions of skeletal system

Axial skeleton (Human)

It occupies the body's main longitudinal axis. It includes four structure : skull in the head, vertebral column in the neck, trunk and tail if present, sternum and ribs in the thorax. It form the upright axis of body and includes 80 (87 in children) bones as follows in man –

Cranium – 8	28 Skull	Hyoid – 1
Face – 14		Vertebrae – 26 (in children 33)
Ear ossicle – 6		Sternum – 1
		Ribs – 24

Skull (General structure) : It is the anterior most axial skeleton. It is divisible into two main parts –

(i) Chondrocranium (ii) Splanchnocranium

(i) **Chondrocranium** : Chondrocranium is formed by (a) brain box or cranium proper and (b) two sense capsules – Orbit or optic capsule (eye) and auditory or otic capsule (ear).

(a) **Cranium proper** : It is a strong and firm bony box with a helmet-like covering over the brain, called vault of skull, and a relatively thicker and stronger floor of base upon which the brain rests. Its cavity is called cranial cavity. Size of cranial cavity averages 1475 cubic centimetres (cm^3) in adult men. At about the middle of the floor of cranium, there is a large opening of cranial cavity called foramen magnum. The brain is connected to spinal cord at this foramen. Cranium proper of mammal has following distinct zones –

❑ **Occipital zone :** Occipital zone has one supra-occipital bone on dorsal side, one basioccipital on ventral side and two exoccipital on both lateral side of foramen magnum. Foramen magnum is present in ventral side of skull, which fits on Ist atlas vertebra. Two occipital condyles forming dicondylic skull at the junction of supra and exo-occipital.

❑ **Parietal zone :** In the dorsal side of cranium parietal zone has three bone, that is two parietal, one inter parietal and ventral side of cranium has 3 bone *i.e.* one basisphenoid with pituitary foramen and two alisphenoid bone.

❑ **Frontal :** Frontal part of cranium has two frontal bone in dorsal side, each frontal bone has one process called supra orbital process of frontal. Two orbitosphenoid, one presphenoid bone in ventral side.

❑ **Ethmoidal :** Ethmoidal part has one circular plate called cribriformplate. That plate is having two perforation for exit of I cranial nerve.

(b) **Sense capsule :** Chondrocranium contains two sense capsule.

❑ Optic or orbital capsule

❑ Otic or auditory capsule

Optic capsule : One pair of optic or orbital capsule is present in frontal zone of chondrocranium. It is made up of 7 pairs of bones which are –

I – Pre frontal II – Post frontal III – Anterior orbital

IV – Posterior orbital V – Infra orbital VI – Supra orbital

VII – Lacrimal

In frog optic capsules are absent but in place of optic capsule eye-orbit are present in same position. In between two eye capsule, a separating bone is present in mammals only. This separating bone is called inter-orbital septum. This septum is absent in frog between two eye orbits.

Auditory or Otic capsule : Auditory capsule is located between occipital and parietal zone. It has two parts – Tympanic bulla and External auditory meatus. Auditory capsule in vertebrates is formed by 5 pairs of otic bones.

(I) Preotic (II) Epiotic (III) Opisthotic (IV) Sphaenotic

(V) Pterotic

Out of these 5 pairs only I pair i.e. preotic participate in formation of auditory capsule of frog i.e. amphibian. In mammals *e.g.*, rabbit I, II & III pair fuse to form a fusion bone called periotic, which forms the auditory capsule. In reptiles and birds (aves) all 5 pairs bone together constitute auditory capsule. Membranous labyrinth is enclosed in the preotic and tympanic bulla. Auditory capsule has two distinct part – Outer spongy part called petrous part and inner bony part called mastoid part.

(ii) **Splanchnocranium :** It is also known as facial. It includes following parts –

❑ **Visceral skeleton :** Visceral skeleton is formed by pairs of visceral arches which are –

Mandibular arch (I pair of visceral arch) : It is made of two arches one is upper forming upper jaw and second is lower called lower jaw. In tadpole stage upper jaw i.e. upper part of mandibular arch is formed by the fusion of three cartilage called palatine, pterygoid and quadrate. These all fused to form palato-pterygoquadrate.

Lower jaw or II part of mandibular arch is cartilagenous initially and is called Meckel's cartilage which soon changes into bony structure.

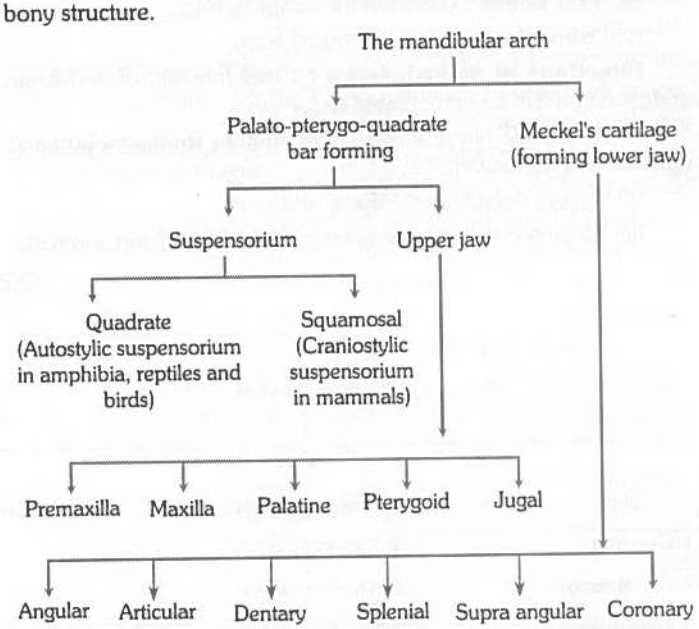

(a) **Upper jaw :** The upper jaw is made of 14 bones i.e. 7 pairs of bones which are – Premaxilla, Maxilla, Jugal, Squamosal, Pterygoid, Palatine, Quadrate.

Out of these 7 pairs of bones only quadrate are not visible because they constitute II ear ossicle i.e. – incus. In man the nasal cavity is separated from the buccal cavity by bone called palatine complex. Palate of birds is identical in animal kingdom, which is used for birds classification.

Process of upper jaw

Premaxilla : Nasal process on dorsal side which are covered by Nasal; Palatine process of premaxilla.

Maxilla : Nasal process of maxilla; Palatine process of maxilla; Zygomatic process of maxilla.

Squamosal : Only zygomatic process of squamosal.

(b) **Lower jaw :** It is composed of 6 pairs of bone *i.e.* 12 bones maximum. These are articular, angular, splenial, dentary, coronoid and supra angular.

In frog out of 6 pairs only 4 pairs of bones are present. Only 3 pairs form lower jaw and one pair forms I ear ossicle i.e. collumella auris. Remaining 3 pairs i.e. Angular, splenial and dentary combine to form lower jaw of frog. In mammals only one pair of bones are present of which only one pair i.e. dentary forms lower jaw.

Upper jaw in vertebrates is completely ossified with skull but lower jaw is always free from chondrocranium and hangs downwardly. A bone hangs lower jaw from upper jaw. This bone is called suspensorium. A skull in which suspensorium is formed by quadrate is called autostylic skull *e.g.*, frog skull. A skull in which suspensorium is formed by squamosal is called craniostylic skull *e.g.*, rabbit skull (all mammal).

Hyoid arch (II pair of visceral arch) : It is also one pair which is called Hyoid proper and Hyomandibular.

(a) **Hyoid proper :** It is a horse-shoe shaped bone in our neck between lower jaw and sound box or larynx. It is not articulate to any bone but is simply suspended from temporal bones by means of ligament. It consists of an elliptical main part or body and two processes on each side of body, called greater and lesser cornua. It supports our tongue and provides insertion to some tongue muscles. In colloboration with branchial arches forms hyoid apparatus in terrestrial vertebrates. It is absent in fishes because branchial arches form gill rackers which support gills.

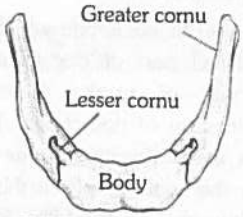

Fig. 5.5-2 : Human hyoid bone viewed from above

(b) **Hyomandibular :** It is second part of hyoid arch which constitutes ear ossicles in vertebrate. In frog hyomandibular forms stapidial plate which is IIear ossicle which is dot or lid like bone. In rabbit hyomandibular forms stapes which is III ear ossicle. That is stirrup like bone.

Table : 5.5-1 Ear ossicles

I	II	III
Malleus	Incus	Stapes
Articular	Quadrate	Hyomandibular
Hammer	Anvil	Stirrup

Branchial arches (III to VII pair of Visceral arches) : These are five pairs, which constitute III to VII pair of visceral arches. These constitute gill racker in fishes but terrestrial animals then form hyoid apparatus in collaboration with hyoid proper. Five pairs of branchial arches are as follows –

(a) III pair ceratohyle. (b) IV pair i.e. is epihyal.
(c) V pair i.e. is stylohyal. (d) VI pair i.e. tympanohyal.
(e) VII pair i.e. thyrohyal.

Skull of man

In man however the skull remain erect at top of vertebral column because of perfectly erect posture of body it is divisible into the large and hollow cranium and the facial region together protects and support some useful organ for vision, taste, smell, hearing and equilibrium.

(1) **Cranium (Brain case) :** Cranium stabilize the position of brain. In skull of man all eight bones are articulated with each other to form the cranium as follows –

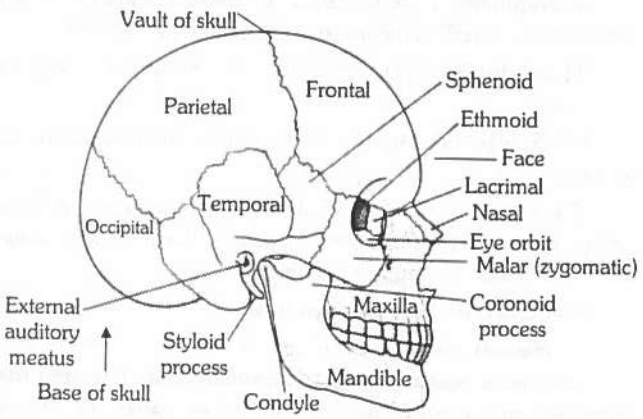

Fig : 5.5-3 Human skull viewed from right side

Table : 5.5-2 Bones of cranium

Name	No.	Description
Frontal	1	Forms the forehead (anterior or front part of the top of cranium) and some upper parts (roofs) of eye orbits or sockets and nasal cavities. A newborn infant displays a faint suture in midline of frontal, indicating that adult frontal is actually formed of two completely fused frontal. Frontal suture between two frontal disappear by age 6 years. If persists throughout life referred as metopic sutures.
Parietals	2	Articulated to and situated just behind frontal. Form the main parts of bulging top and sides of cranium.
Occipital	1	Articulated to and situated just behind parietals. Forms posterior (back) and lower (base) parts of cranium. Foramen magnum is a large perforation in this bone. On each side of the foramen, the occipital bears a prominent elevation called occipital condyle. The condyles articulate the skull with first vertebra (atlas). Thus, human skull is dicondylic.
Temporals	2	Form lower parts of right and left sides of cranium, as well as, the floor of cranial cavity. These house structures of internal and middle ears and form a part of external auditory meatus. The middle ear of each side encloses the three small ear ossicles – malleus, incus and stapes. The mastoid process with mastoid air cells in adult.
Sphenoid	1	A typically butterfly-shaped bone that forms the middle and anterior parts of base of cranium in front of occipital in the middle and temporals on the sides. It articulates with all skull bones, keeping these firmly together. It also forms parts of lateral walls and floors of eye orbits. Sphenoid with sella turcica depression for pituitary body.
Ethmoid	1	A small, irregular bone in front of sphenoid and behind nasal bones. It fashions the front (anterior) extremity and closer of cranial cavity. It also contributes to the architecture of eye orbits and proximal parts of nasal chambers.

(2) **The facial region :** This is the front or anterior part of our skull comprising of 14 bones as follows :

Table : 5.5-3 Facial bones

Name	No.	Description
Nasals	2	Small, oblong bones in middle of upper part of face, forming proximal part of the bridge of our nose. The remaining, lower part of our nose is formed of cartilage.
Inferior nasal conchae (Turbinates)	2	Two highly coiled, scroll-like processes of ethmoid bone, called conchae project into each nasal cavity from lateral wall of the proximal bony part of concerned nasal chamber. One ethmoidal concha is superior (uppermost). The other one is called middle concha, because it is followed by a thin, separate scroll-like bone which is named inferior nasal concha or turbinate.
Vomer	1	A thin, elongated, platelike bone, forming a part of the septum which separates the two nasal cavities.
Lacrimals	2	Small and thin, finger-shaped bones, each located in front part of the medial (inner) side of corresponding eye orbit. these form a part of the passages of corresponding tear ducts.
Zygomatics (Malars)	2	Cheek-bones; form the prominences of our cheeks and parts of the floor and side walls of eye orbits.
Palatines	2	L-shaped bones that form the back (posterior) part of our hard palate (roof of mouth). Also contribute to the framework of nasal cavities and floor of eye orbits.
Maxillae	2	Large, upper jaw bones that form the major part of our face and upper jaw. Comprise entire front (anterior) part of our hard palate. Also contribute to the architecture of eye orbits and nose. Bear the teeth of upper jaw.
Mandible	1	Largest bone of our face, and strongest of all bones of the body. Forms entire lower jaw and bears all lower jaw teeth. Articulated with temporal bones of skull. Only skull bone that moves.

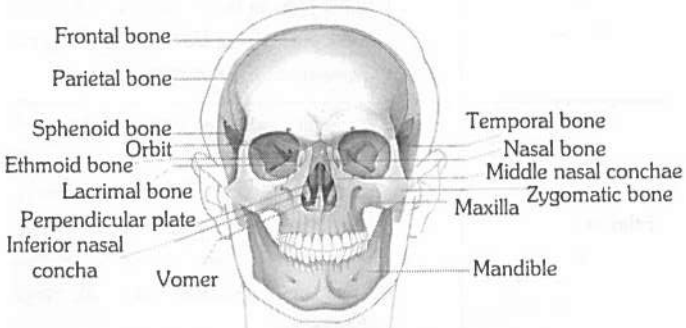

Fig : 5.5-4 Human skull viewed from the front

Vertebral column

It is our backbone which extends in the mid axis of the back (posterior) part of our trunk from head to the lower (inferior) extremity of trunk. Vertebral column of vertebrates is a modification of notochord. Together with the sternum and rib, it forms the supporting frame work of our trunk. It supports and rotate the head, suspends the viscera, protect vital organs, provides attachment to limb girdles, facilitates some movement of the trunk and houses the spinal cord. Vertebral column make two-fifth of total weight of body. The length of human vertebral column is 71 *cm.* (28 Inc.) in adult male and about. 61 *cm* (24 inches) in an average adult female.

Curvatures of vertebral column : In a foetus, there is only a single anteriorly concave curve, in adult there are 4 curves like, cervical, thoracic, lumbar, and sacral. Cervical and lumbar are anteriorly convex, while thoracic and sacral are anteriorly concave. At approximately 3rd month after birth, when an infant begins to hold its head erect, cervical curves develops. Later, when the child sits up, stands, and walks, the lumbar curves develops. The thoracic and sacral curves retains anterior concavity of foetus thus are called 'Primary curves' . The cervical and lumbar curves are modification of the original foetal curves, and are called as "Secondary curves".

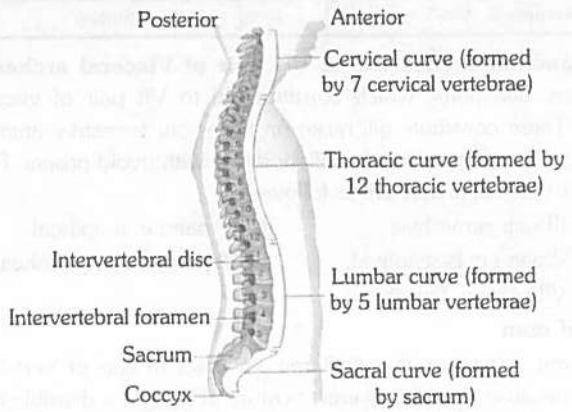

Fig : 5.5-5 Right lateral view showing four normal curves

The curves of vertebral column are important because they increases its strength, help to maintain balance in upright position absorb shock during walking and running and help to protect the column from fracture. Certain abnormalities of curvature are :

(i) **Kyphosis :** Exaggeration of thoracic curve, resulting in "round-shouldered" appearance, also called hunch back.

(ii) **Lordosis** : An exaggeration of lumbar curve, also called sway back.

(iii) **Scoliosis :** An abnormal lateral curvature in any region of spine.

The vestigeal notochord called nucleus pulposus is found in intervertebral disc. Inter-vertebral disc is fibro cartilagenous disc present between centrum of vertebrae.

Structure of Typical vertebrae

(1) **Neural arch :** It arises from the dorsal side of the centrum and encloses a neural canal for the spinal cord. The arch may be produced into a dorsal process, the neural spine, which may be elongated pointed or flattened and directed upwards or backwards.

(2) **Transverse processes :** These are lateral extension of neural arch and centrum. There may be two types of these processes a more dorsal diapophysis arising from the base of neural arch and a lateral parapophysis arising from the side of the centrum.

(i) **Diapophysis (*dia*- two; *apo*- from; *physis* – growth) :** These paired processes are directed differently and provide attachment to the tubercular processes of ribs. They are commonly known as transverse processes and are found in amphibians and other higher vertebrates.

(ii) **Parapophysis :** These paired outgrowths are similar to diapophysis and are common in fishes.

(iii) **Zygapophysis :** These are paired and flat articular surfaces, which check the dislocation of the vertebrae. These are the only structures which enable to identify the anterior and posterior faces of vertebra.

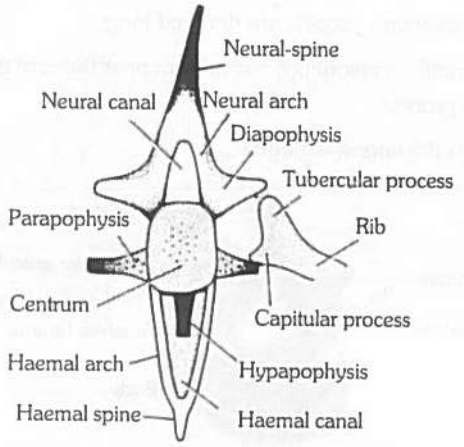

Fig : 5.5-6 Hypothetical typical vertebra (front view)

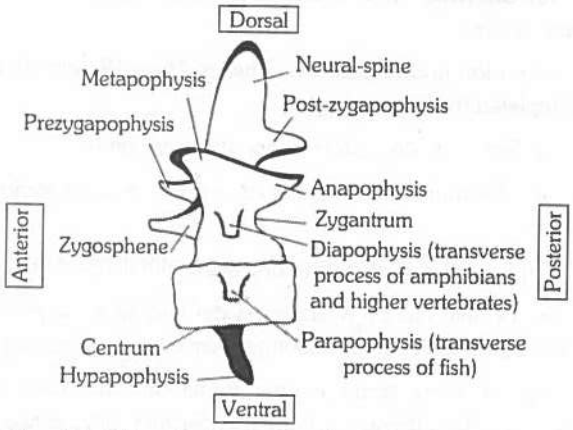

Fig : 5.5-7 Hypothetical typical vertebra (side view)

(iv) **Hypapophysis :** It is a mid-ventral process which arises from the centrum. It may be directed forwards or backwards as in certain reptilian, avian and mammalian vertebrae.

(v) **Metapophysis :** These are paired swellings or out growths having broad base and arising from just above the prezygapophyses. They are directed forwards and upwards, but their articular facets look slightly downwards. They are found in certain mammalian vertebrae.

(vi) **Anapophysis :** These are paired, slender and short processes which arise just below the postzygapophysis. Their articular facets look-slightly upwards and receive for the matapophysis.

(3) **Heamal arch :** It surrounds the haemal canal which allows the blood vessels of the tail region to pass. It may be produced into a haemal spine below *e.g.*, in fishes. The haemal arch of the caudal vertebrae of reptiles is called chevron bone. It is usually Y-shaped.

(4) **Centrum :** The part of vertebra attached to second by centrum. On the basis of centrum vertebrae may be of following type–

(i) **Procoelous-vertebrae** : Anterior end is concave and posterior end is convex. *e.g.*, 2nd to 7th vertebra of frog. Reptile (Lizard)

(ii) **Ophisthocoelous vertebrae :** Anterior end is convex and posterior end is concave. *e.g.*, Fishes, snake and crocodile only.

(iii) **Heterocoelous vertebrae :** Anteriorly convex from dorsal to ventral and concave from side to side. On posterior side concave from dorsal to ventral and convex from side to side (saddle shaped). *e.g.*, Birds.

(iv) **Acoelous vertebrae :** Also known as Amphiplatyon. No cavity in centrum so centrum is flat. *e.g.*, Mammals (man, Rabbit).

(v) **Amphicoelous vertebrae** : Cavity present on both side of centrum. *e.g.*, VIIIth vertebra of frog. All veretebrae of scoliodon (Dog fish)

(vi) **Amphidicondylar (Biconvex)** : Biconvex, condyle on both side. *e.g.*, IXth vertebra of frog.

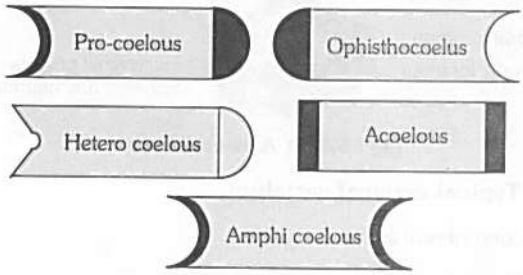

Fig : 5.5-8 Types of Centrum

Vertebral column of man : Made up of pieces of bones known as vertebrae. Vertebrae of man are acoelous *i.e.* Centrum is flat and without cavity (Amphiplatyon). Vertebral column is also known as spinal column or backbone.

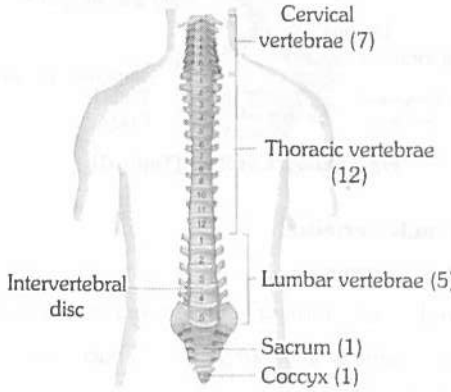

Fig : 5.5-9 Anterior view showing regions of the vertebral column

(1) **Atlas vertebra**

(i) First cervical vertebra.

(ii) Body is formed of vertebral arch transverse process.

(iii) It supports the globe of the head like the earth by the atlas (super man).

(iv) Centrum is absent.

(v) Neural spine absent.

(vi) Transverse process are long with transverse foramen.

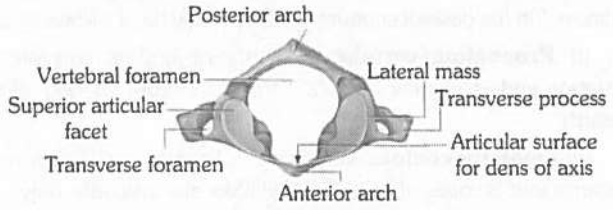

Fig : 5.5-10 Atlas

(2) **Axis vertebra**

(i) Second cervical vertebra.

(ii) Centrum acoelus.

(iii) Odontoid process or dens present, which is modified centrum of Atlas.

(iv) It is pivot for rotation of atlas and head around odontoid process. Transverse process small.

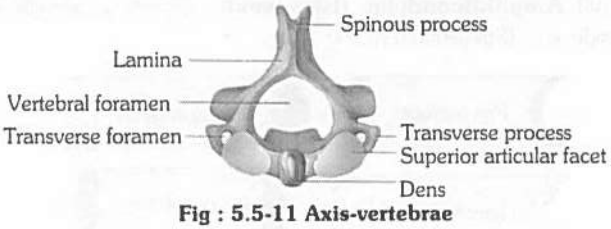

Fig : 5.5-11 Axis-vertebrae

(3) **Typical cervical vertebra**

(i) Long neural spine.

(ii) Centrum acoelus.

(iii) Transverse process are large.

(iv) Vertebrarteal canals present.

(v) Vertebrarteal canals also known as foramina transversaria.

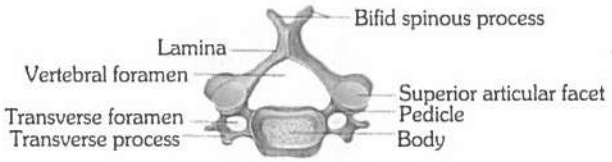

Fig : 5.5-12 Cervical (Typical)

(4) **Thoracic vertebra**

(i) Centrum acoelus.

(ii) Neural canal is formed by union of two neural arches.

(iii) Neural spine is flat & long directed backward.

(iv) Club shaped transverse process.

(v) Neural arch with superior articular process.

(vi) Two demifacets for articulation of head of a rib are present.

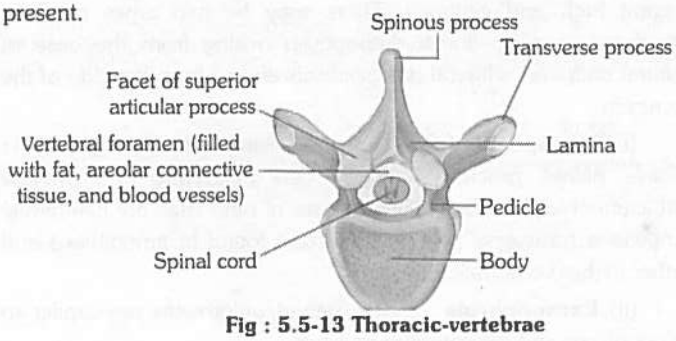

Fig : 5.5-13 Thoracic-vertebrae

(5) **Lumbar vertebra**

(i) Centrum acoelus.

(ii) Neural spine well developed.

(iii) Transverse process are thin and long.

(iv) Small accessory process present near the root of each transverse process.

(v) It is the largest vertebrae.

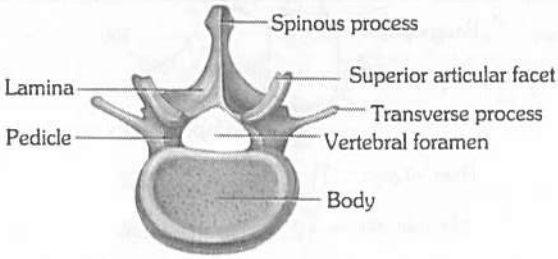

Fig : 5.5-14 Lumbar-vertebrae

(6) **Sacrum :** It is a triangular bone formed by fusion of 5 sacral vertebra.

(i) Fusion normally begins between 16 to 18 years of age and is completed by 30 yrs. of age.

(ii) Serves as strong foundation for pelvic girdle.

(iii) Sacrum with 4 pairs of anterior and posterior sacral foramina.

(iv) Lateral part of sacrum articulate with ilium of hip bone.

(v) Female sacrum is shorter, wider and more curved between S_2 and S_3 the male sacrum is longer, narrower, and less curved.

(vi) In birds some of the vertebrae are fused to form synsacrum. [Last thoracic+ Lumbar+ Sacral+ One or two caudal]

(7) **Coccyx**

(i) It is formed by fusion of four coccygeal vertebrae.

(ii) It is last section of backbone.

(iii) It is small triangular bone.

(iv) Two coccygeal cornua project upto articulate with sacral cornua.

(v) Rudimentary transverse process.

(vi) Fusion generally occurs between 20 and 30 years of age.

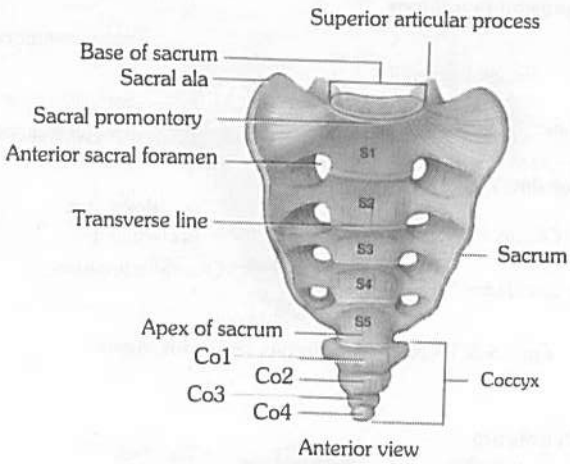

Fig : 5.5-15 Human sacrum and coccyx

Thoracic basket

(1) **Ribs**

Structure : The ribs are curved bars, which movably articulate with the thoracic vertebrae at the back and while with the sternum in front all collectively forming a bony cage, the thoracic basket. These are 12 pairs of ribs. The upper seven pairs of ribs are attached in front directly to the sternum by hyaline cartilage. These are called true rib. The next three pairs of rib costal cartilage attach indirectly to sterum. They are termed false ribs. The lower two pair of ribs are free in front they are known as floating ribs. Tenth rib is also usually floating in Japanese and some other people.

A rib consists of two parts, Vertebral and Sternal. The vertebral part is long and bony. It articulate with the thoracic vertebrae by 2 facets, the capitulum and tuberculum, (Ribs of mammal and birds are bicephalous) in the first nine ribs and by a single facet, the head in the remaining vertebrae. The sternal part is short and cartilaginous. It articulate with the sternum or sternal part of its upper rib.

Human thorax is wider from side to side then from front to back. This is an adaptation for the up right posture of the body. It help to maintain equilibrium. In birds an uncinate process is present in ribs for muscles attachment.

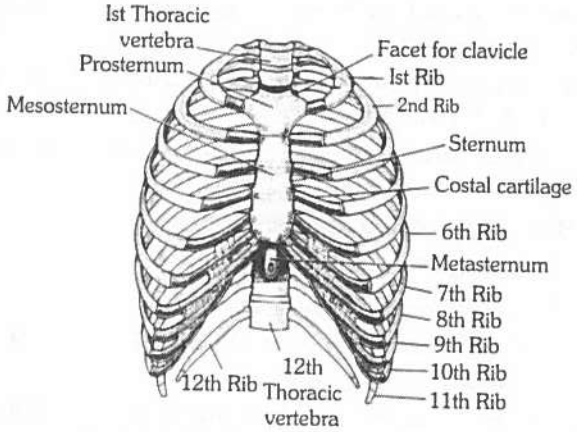

Fig : 5.5-16 Bones of thorax (front view)

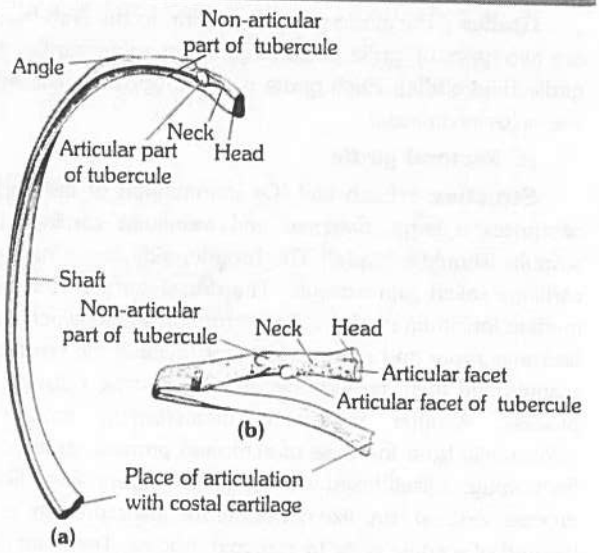

Fig : 5.5-17 A typical rib of left side (a) Inferior aspect; (b) Posterior aspect

Function : The ribs serve three important functions –

(i) They protect the heart, large blood vessels and lungs.

(ii) They bear respiratory muscle (external and internal intercostal muscle).

(iii) Lower two pair of ribs protect the kidney. (11th and 12th)

(2) **Sternum**

Structure

(i) It is a bone of chest.

(ii) It is absent in fish, Turtle.

(iii) It is associated with pectoral girdle in amphibia.

(iv) In man it is made up of cervical manubrium (presternum), mesosternum and xiphoid process (Metasternum).

(v) In male it is nearly 17 cm long.

(vi) Manubrium is broad and thick.

(vii) Mesosternum is made up fine sternebrae.

(viii) Metasternum is represented by xiphisternum which is smallest broad and thin. In mammal a cartilagenous plate is attached with xiphisternum known as xiphoid cartilage (hyaline).

❑ Sternum = manubrium + 5 sternebrae + xiphisternum.

Function : The sternum has two function –

(i) It takes part in the formation of the protective thoracic basket.

(ii) It plays a role in the respiratory mechanism.

Appendicular skeleton

It forms the bony frameworks of limbs and their supporting girdles, and includes 126 bones as follows –

1. Upper extermities	2. Lower extermities
(i) Pectoral girdle — Clavicle (2), Scapula (2)	(i) Pelvic girdle 2
(ii) Upper limbs (arms) 60	(ii) Lower limbs 60

Girdles : The girdle give articulation to the limb bones. There are two types of girdle pectoral girdle (shoulder girdle) and pelvic girdle (Hip girdle). Each girdle is made up of similar right and left halves (os innominate).

(1) **Pectoral girdle**

Structure : Each half (Os innominate) of the girdle mainly comprises a large, flattened and triangular cartilage bone, the scapula (shoulder blade). The broader side has a narrow strip of cartilage called suprascapula. The dorsal surface of scapula has a median longitutinal ridge called acromian spine, which successively becomes more and more prominent towards the narrower end of scapula and then, projects beyond this end as a distinct acromian process. Another prominent metacromian process projects horizontally from the base of acromian process. At its narrow end, the scapula is itself fused with an inwardly bent, knob like coracoid process. A deep, cup like concavity the glenoid cavity is located at the end of scapula close to coracoid process. The head of humerus (bone of upper arm) fits into this cavity. Another component of each half of pectoral girdle is a long and slender, rod-like membrane bone the clavicle, articulated with the acromian process. The other end of clavicle is connected with pre sternum by means of an elastic ligament. Clavicle is also called collar bone.

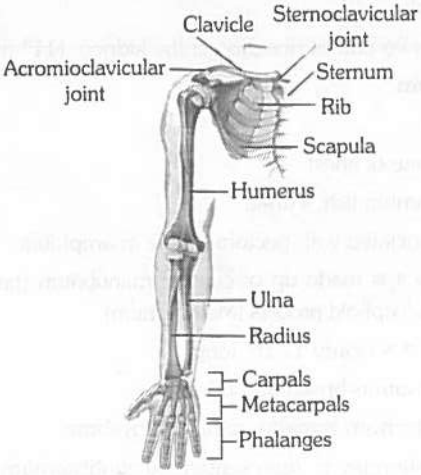

Fig : 5.5-18 Scapula-pectoral girdle

Function : The pectoral girdle serves two functions –

(i) It provides articulation to the arm bones.

(ii) It affords attachment to certain muscles of the arm.

(2) **Pelvic (Hip) girdle**

Structure : It is located in the lower part of the trunk. It consists of 3 bones – upper ilium, lower ischium and inner pubis, fused to form a stout hip bone, the innominate. Ventral wall of pubis has a small bone called cotyloid. Acetabulum is formed by ilium, ischium and pubis, but in mammals pubis is replaced by cotyloid bone. Pubic symphysis is present in mammals. Below the acetabulum, the innominate has a large oval gap, the obturator foramen (ischio-pubic foramen) . The two innominate bones and sacrum together form a sort of bowel, the pelvis, that supports the lower abdominal viscera. This is also an adaptation for upright posture of the human body. The female pelvis is larger and has a broader front and larger bottom opening than the male pelvis. This is an adaptation for childbirth. In man ischial tuberosity or siting bone is present in ischium.

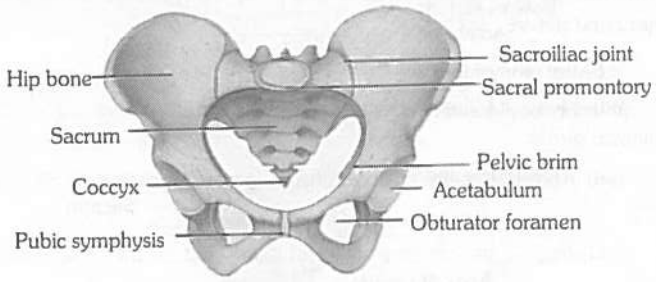

Fig : 5.5-19 Man-male pelvis (Anterior view)

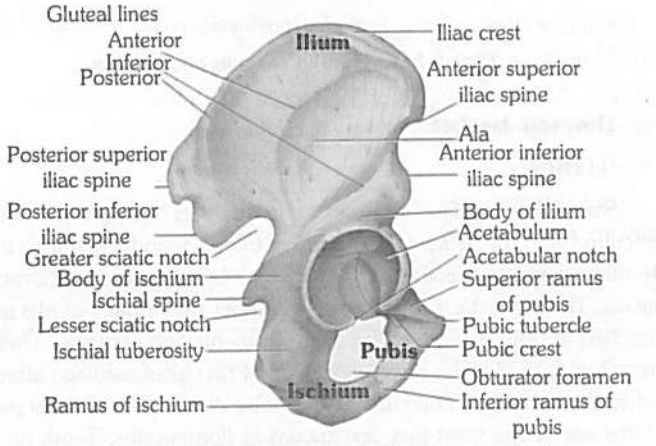

Fig : 5.5-20 Man-pelvic girdle (Lateral view)

Functions : The pelvic girdle serves the following functions –

(i) It provides articulation to the bones of the leg.

(ii) It contributes to the formation of a bowel for the support and protection of abdominal viscera.

(iii) It transfers the weight of the body to the leg.

(iv) It provides the attachment to certain leg muscles.

(v) Support vertebral column.

Limb bones : Limb are of two types fore limb and hind limb.

(1) **Bones of fore limbs**

Structure

(i) Humerus or arm bone or bone of upper arm, is longest and largest bone of upper limb.

(ii) It articulates proximally with scapula and distally at the elbow with both ulna and radius.

(iii) Humerus proximal end with greater and lesser tuberosity tubercle.

(iv) Both radius and ulna with nutrient foramina.

(v) Radius present towards thumb side.

(vi) Ulna present towards little finger side.

(vii) It includes Humerus + Radius & ulna + Carpals + Meta carpals + Phalanges.

(viii) Humerus is characterised by the presence of deltoid tuberosity for the attachment of muscles.

(ix) Distal end of humerus at the elbow joint is like pully and called trochlea. Its groove is called olecranon fossa whose basal part is marked by a supratrochlear foramen for the passage of brachial artery and nerve.

(x) Humerus is characterised by arterial foramen.

(xi) Head of the humerus articulate with glenoid cavity of pectoral girdle.

(xii) Radius is smaller and ulna is larger, were bones of fore arm.

(xiii) Styloid process is present in distal end of ulna and radius both.

(xiv) Olecranon process is present in ulna. Proximally, which forms prominence of elbow.

(xv) Trochlear notch is formed by ulna which is also known as sigmoid notch.

(xvi) Carpals or wrist bone are eight in number, joined to one another by ligaments. Carpals are arranged in 2 rows, with 4 bones in each row.

(xvii) Metacarpals are five in number, and phalanges are – fourteen, phalanges formula = 2, 3, 3, 3, 3.

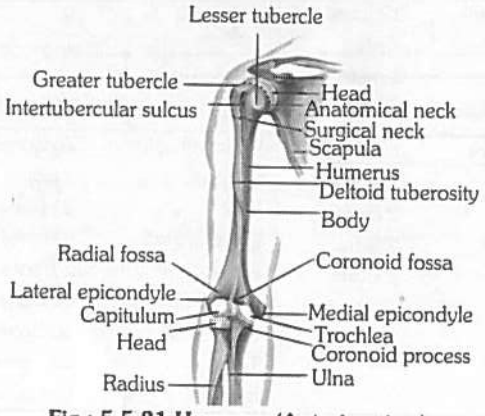

Fig : 5.5-21 Humerus (Anterior view)

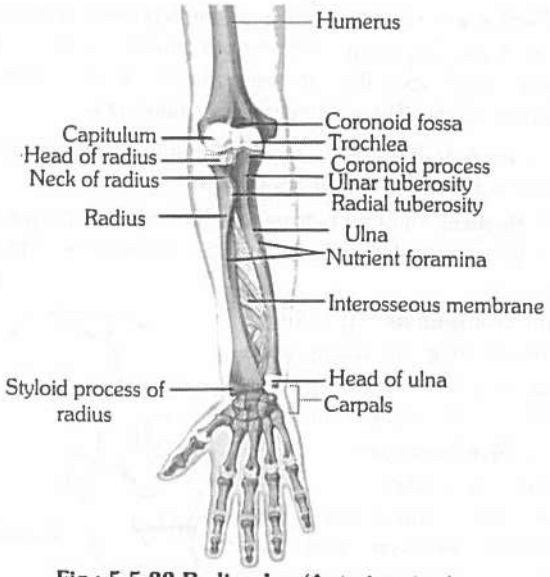

Fig : 5.5-22 Radio-ulna (Anterior view)

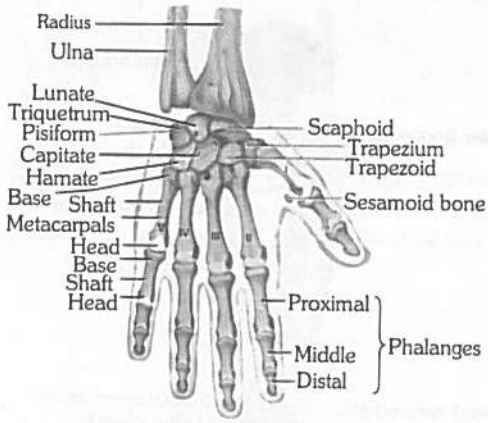

Fig : 5.5-23 Hand (Posterior view)

Special features : In the human arm, (i) The joints are more movable than in the forelimbs of animals (ii) Metacarpals form a wide palm and (iii) Thumb is opposable. The differences in structure are correlated to the differences in function. Animals use their forelimbs mainly for locomotion whereas man uses the arms for work (grasping).

Function : Bones of the arms provide strength to make the arms effective in working with them.

(2) **Bones of hind limbs**

Structures

(i) It includes Femur + Tibia and Fibula + Tarsals + Metatarsals + Phalanges

(ii) Fovea capitis is depression in head of femur.

(iii) Femur is longest and strongest bone of body.

(iv) Femur is known as bone of thigh

(v) Greater trochanter, lesser trochanter 3rd trochanter are present in femur, of thigh and buttock muscles.

(vi) Patellar groove is found in distal end of femur.

(vii) Fibula is smaller and associated with knee joint.

(viii) Tibia is larger, also called shin bone. It bears a weight of body.

(ix) Tarsal bones are seven.

(x) Metatarsals are five.

(xi) Phalanges are fourteen.

(xii) Phalanges formula = 2, 3, 3, 3, 3

(xiii) Patella form knee cap.

(xiv) Patella is formed by sesamoid bone. Fabella also example of sesamoid bone.

(xv) Thumb of foot is called hallux.

(xvi) Ankle bones have 7 tarsals and arranged in two rows. The first row have talus and calcaneus and second row with cuboid, Navicular, and I, II, III cuneiform.

(xvii) Nutrient foramen present in Tibio - fibula bone. Tibia fibula is longest bone in frog.

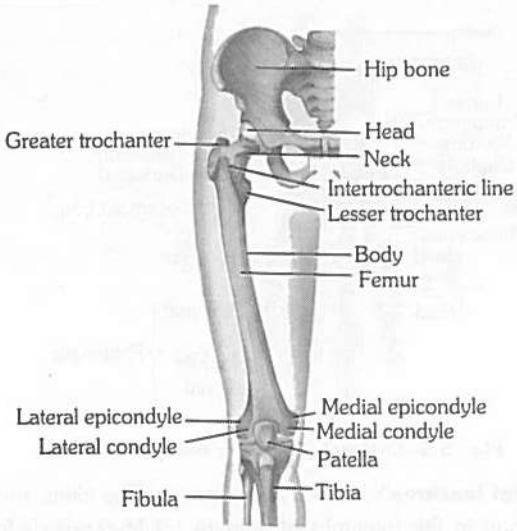

Fig : 5.5-24 Femur (Anterior view)

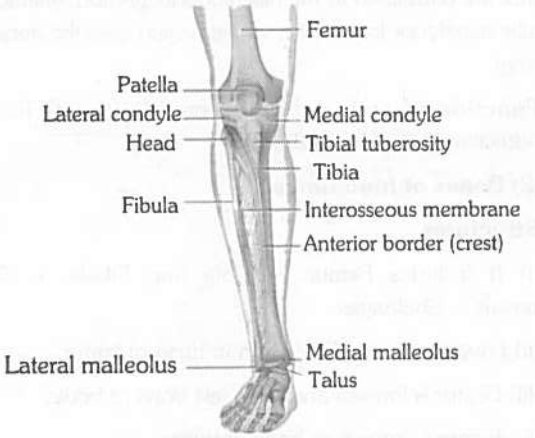

Fig : 5.5-25 Tibia-fibula (Anterior view)

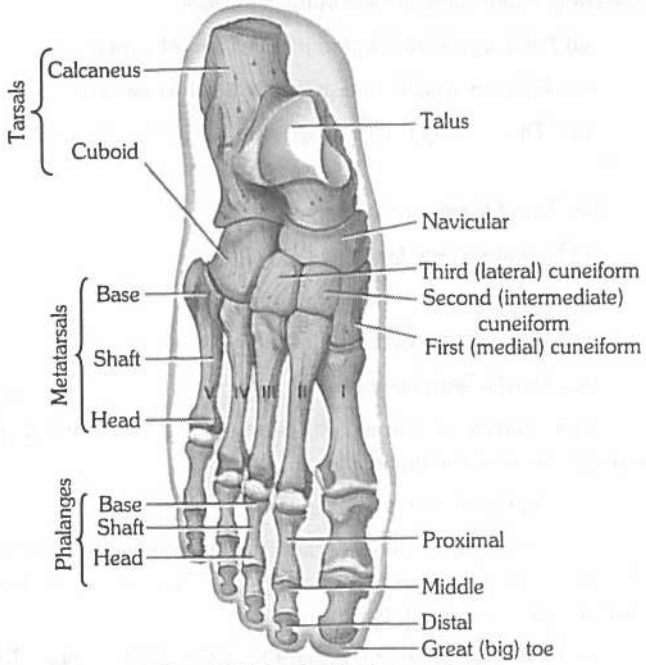

Fig : 5.5-26 Foot (Inferior view)

Special features : All the bones of the legs are more massive than the bones of the arms because the legs alone support the body on the ground and are used in locomotion. The broad feet provide an additional stable support in the upright posture.

Function : The bones strengthen the legs to bear body weight, to balance the body while standing and to aid in locomotion.

Table : 5.5-4 Total number of skeletal bones : 206 Bones

Skull : 29 Bones		Facial region : 14 Bones	
Cranium : 8 Bones		Nasals : 2 Bones	
Occipital : 1 Bone		Vomer : 1 Bones	
Parietal : 2 Bones		Turbinates : 2 Bones	
Frontal : 1 Bones		Lacrymal : 2 Bones	
Temporal : 2 Bones		Zygomatic : 2 Bones	
Sphenoid : 1 Bone		Palatine : 2 Bones	
Ethmoid : 1 Bone		Maxilla : 2 Bones	
		Mandible : 1 Bones	
Coccyx : Fusion of 4 coccygeal vertebrae		Vertebral formula = 33 (child)	
In new born baby : 5 sacral vertebrae		C TH L S C ↓ ↓ ↓ ↓ ↓ 7 12 5 5 4	
In adult sacrum : Only one		Sacral coccygeal Vertebral column = 26 (In adult)	
Ribs in man : 12 pairs		C TH L S C	
True ribs : 7 pairs		↓ ↓ ↓ ↓ ↓	
False ribs : 3 pairs		7 12 5 1 1	
Floating ribs : 2 pairs			Sacrum coccyx
Ear ossicles 6 Bones		Vertebral column : 26 Bones	
Malleus : 2 Bones		Sternum : 1 Bone	
Incus : 2 Bones		Ribs : 24 Bone	
Stapes : 2 Bones		Pectoral girdle : 4 Bones	
Hyoid : 1 Bone		Pelvic girdle : 2 Bones	
		Fore limbs : 60 Bones (both)	
		Hind limbs : 60 Bones (both)	
		Total : 206 Bones	
		In child : Bones 330	

Joints

There are many articulations or joints present in the skeleton. Joint or articulation is a point of contact between bones. Joints are classified based upon their structure and the kinds of movements which they permit. Three main types of joints are –

(1) **Immovable joints (Synarthrosis) :** No joint cavity, no movement possible. These joints include –

(i) **Sutures :** Found between skull bones, sutures are fixed or fibrous joints, articulating bones are held together by white fibrous tissue.

(ii) **Gomphosis :** It is a type of fibrous joint in which cone shaped peg fits socket. Teeth in mandibles, and maxillary bones.

(iii) **Syndesmosis :** It is type of fibrous joint with more fibrous tissue than sutures. *e.g.*, distal articulation between tibia and fibula.

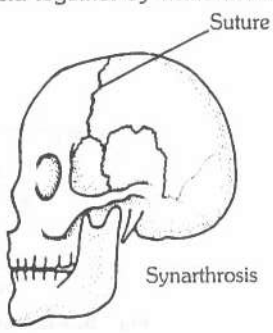

(2) **Imperfect joints (Amphiarthrosis)** slightly movable : Joints in which synovial cavity is absent. Permit a small amount of movement. Fibrocartilage is placed between the bones. These are cartilaginous joints *e.g.*, Pubic symphysis, between bodies of the vertebrae, between the manubrium and the body of sternum, sacroilliac joint in frog.

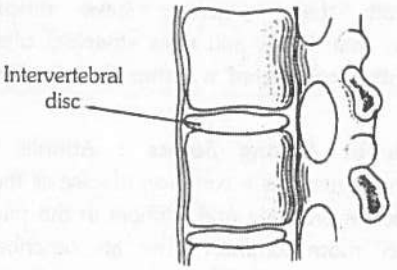

Amphiarthrosis

(3) **Perfect joints (Diarthrosis)** freely movable : Synovial cavity and ligaments are present. These are typical joints having articulate surface and synovial capsule. Synovial fluid act as a grease in the joint *e.g.*, Joints of elbow, ankle, wrist, hip, knee. Articular cartilage covers the surface of articular bones. Articular cartilage of synovial joint is hyaline cartilage. Synovial joints are surrounded by tubular articular capsule. The articular capsule consists of two layers, outer fibrous capsule and inner synovial membrane. The synovial membrane secretes synovial fluid which lubricates and provides nourishment to articular cartilage. In old age stiffness of joints is due to the decrease in synovial fluid.

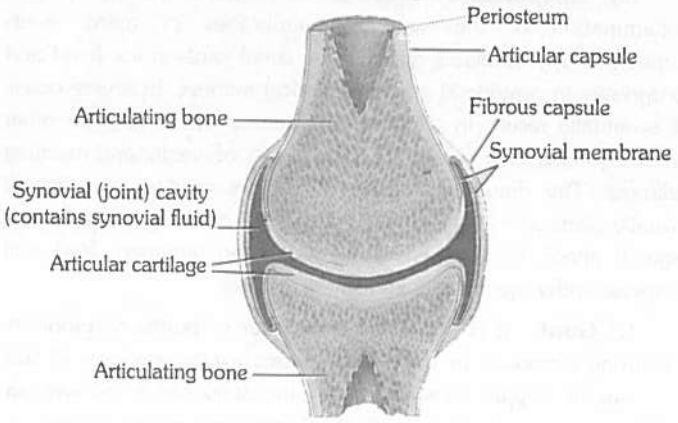

Typical synovial joint (Frontal section)

(i) **Ball and socket joint** : Also known as enarthrosis. Ball of one bone articulate in socket of another bone. *e.g.*, head of humerus and glenoid cavity of pectoral girdle, femur and acetabulum of pelvic girdle, joint between incus and stapes.

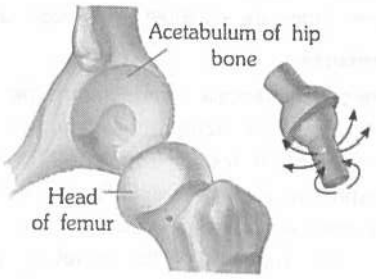

Fig : 5.5-27 Ball-and-socket joint between head of the femur and acetabulum of the hip bone

(ii) **Hinge joint** : Also known as gingulum. Movement is possible in one direction only. *e.g.*, Joint of malleus and incus, knee joint, elbow joint, articulation joint of lower jaw, joint of phalanges of digits.

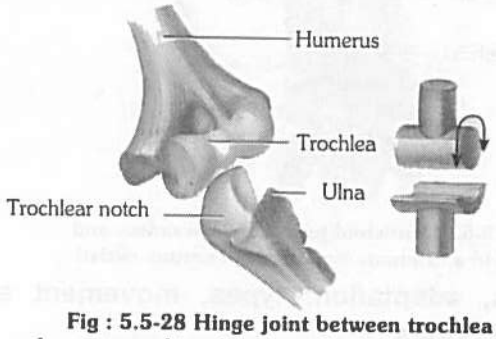

Fig : 5.5-28 Hinge joint between trochlea of humerus and trochlear notch of ulna at the elbow

(iii) **Pivot joint** : Also known as rotatoria and helps in turning movement. One bone is fixed and second articulate. *e.g.*, Atlas and axial of skull rotate with axis vertebra also known as atlanto axial joint.

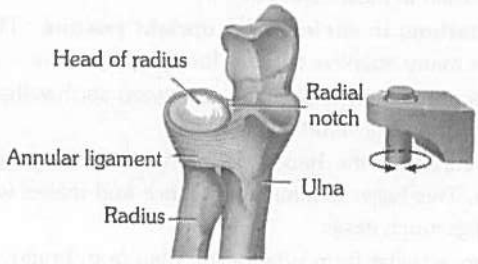

Fig : 5.5-29 Pivot joint between head of radius and radial notch of ulna

(iv) **Gliding joint** : Also known as arthrodial, limited movement in all direction. *e.g.*, Tarsals bones of ankle zygapophysis of vertebrae, Radius and Ulna.

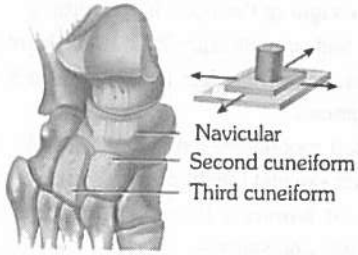

Fig : 5.5-30 Gliding joint between the navicular and second and third cuneiforms of the tarsus in the foot

(v) **Saddle joint** : It is ball and socket like joint but not developed fully. *e.g.*, metacarpal of thumb, and carpals of hand.

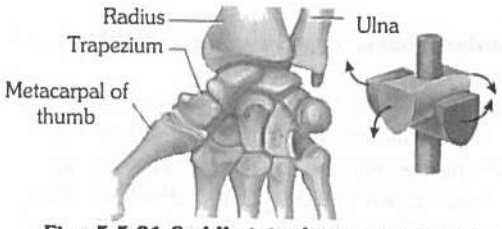

Fig : 5.5-31 Saddle joint between trapezium of carpus (wrist) and metacarpal of thumb

(vi) **Condyloid joint :** Also known as ellipsoidal joint is biaxial where oval condyle of one bone fits into an elliptical cavity of another bone. *e.g.*, joint between radius and carpals at wrist.

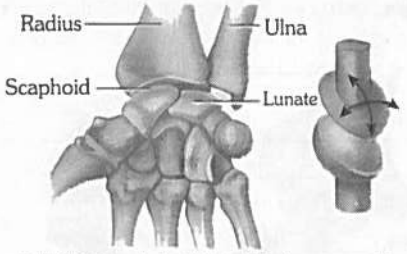

Fig : 5.5-32 Condyloid joint between radius and scaphoid and lunate bones of the carpus (wrist)

Characters, adaptation, types, movement and disorder of bones

(1) **Characteristics of female's skeleton :** In female's skeleton, (i) skull is lighter, (ii) shoulders are narrower (iii) sacrum is shorter but wider, (iv) pelvis is wider, has a broader front and larger bottom opening to facilitate child birth, and (v) coccyx is more movable than in male's skeleton.

(2) **Adaptations in skeleton for upright posture :** Human skeleton shows many adaptive features for upright posture –

(i) Foramen magnum is directed downward so that the head may rest vertically on the vertebral column.

(ii) Four curves in the backbone keep the centre of gravity near the heels. This helps to maintain balance and makes walking erect on two legs much easier.

(iii) Thorax is wider from side-to-side than from front-to-back. This helps to maintain equilibrium.

(iv) Bowel-like pelvis supports the lower abdominal viscera.

(v) Metacarpals form a wide palm and the pollex is opposable. This make the hand a grasping organ to work with it.

(vi) Leg bones are stronger than the arm bones as the femur carry the entire weight of the body in locomotion.

(vii) Broad feet provide stability in the upright posture.

(viii) The arches of the feet enable the body to move with a degree of springiness.

(ix) Increased mobility of the neck to see all round.

(x) Increased skeletal height provides greater range of vision.

(3) **Types of bones :** Bones are divided into 4 categories regarding their size and shape –

(i) **Long bones**, *e.g.*, humerus of upper arm, radius and ulna of forearm, femur of thigh, and tibia and fibula of leg.

(ii) **Short bones,** *e.g.*, metacarpals of palm and metatarsals of foot, phalanges of fingers and toes.

(iii) **Flat bones,** *e.g.*, scapula of shoulder girdle, sternum, cranial bones.

(iv) **Irregular bones,** *e.g.*, vertebrae, carpals of wrist and tarsals of ankle.

(4) **Bone movement :** Movements of bones occur only at the joints. The movements are brought about by contractions of skeletal muscles inserted into the articulating bones by firm cords of white fibrous tissue called tendons. Cords of yellow elastic tissue, termed ligaments, stabilise the joints by holding the articulating bones together.

(5) **Disorder of skeleton and joints :** Any violent movement, such as jump, fall or knock, may cause injury to the skeleton. The injury can be of 5 types – sprain, dislocation, fracture, arthritis and slipped disc.

(i) **Sprain :** Sprain refers to injury to a joint capsule, typically involving a stretching or tearing of tendons or ligaments. Unfortunately, both these structures have much poorer regenerative power than bone, and once stretched often remain weak. Sprain is often considered a minor disorder, but it may become chronic.

(ii) **Arthritis or Aching Joints :** Arthritis refers to inflammation of the joints. It is a common disease of the old age. Its common symptoms are pain and stiffness in the joints. It has many forms. Three more common forms are described here – osteoarthritis or degenerative arthritis, the rheumatoid arthritis and gout.

(a) **Osteoarthritis :** Secretion of the lubricating synovial fluid between the bones at the joint stops. The smooth cartilage covering the ends of the bones at the joint wears out due to years of use and is replaced by uneven bony spurs. The joint becomes inflamed, its movement becomes painful, and its function is diminished. Such a stiffness or fixation of a joint is also called ankylosis. The condition of osteoarthritis is more or less permanent. It is common in old persons, mainly affecting weight bearing joints.

(b) **Rheumatoid arthritis :** It is a chronic painful inflammation of the synovial membranes of many joints simultaneously. It usually starts in the small joints in the hand and progresses in centripetal and symmetrical manner. In severe cases, it eventually results in crippling deformities. There may be other manifestations such as fever, anaemia, loss of weight and morning stiffness. The rheumatoid arthritis involves erosion of joints. It usually starts at the age of 20 – 40 years, but may begin at any age. It affects the women more often than the men. Rest and exercise under medical advice may give relief.

(c) **Gout :** It is an inherited disorder of purine metabolism, occurring especially in men. Body forms excess amounts of uric acid and the crystals of sodium urate are deposited in the synovial joints, giving rise to severe arthritis. It generally affects one or two joints only. It is very painful, particularly at night, and makes movement difficult. Redness and tenderness may be noticed in and about the affected joint. Gout generally affects the great toe. Occurrence of gout is related to diet. Persons suffering from gout should avoid meat. There is no cure for arthritis. However, pain relieving (analgesic) drugs are available to give comfort.

(iii) **Osteoporosis**

(a) **Meaning :** Osteoporosis is reduction in bone tissue mass causing weakness of skeletal strength (*G.osteon* = bone, *poros* = pore, *osis* = condition). It results from excessive resorption of calcium and phosphorus from the bone. There is relatively greater loss of trabecular bone than of compact bone. This leads to vertical compression, or crush fracture, of the vertebrae (which consist primarily of trabecular bone), and fracture of the neck of the femur (which has considerable trabecular bone).

(b) **Causes :** Osteoporosis occurs in postmenopausal women and elderly men. It may result from defective intestinal calcium absorption and menopause. Possible environment factors include smoking, excessive drinking, and decreased exercise. Osteoporosis is more common in women than in men, and in older than in middle-aged persons.

(c) **Symptoms :** Symptoms of osteoporosis are pain in the bone, particularly the back, and vertebral crush, usually in weight bearing vertebrae (thoracic-8 and below).

(d) **Prevention :** Preventive measures in high-risk patients include supplementary calcium and exercise, and, in postmenopausal women, estrogen replacement therapy. Supplementary calcium and sex hormones decrease bone resorption and may arrest or reduce disease progression.

(iv) **Dislocation :** Dislocation is displacement of bones from their normal positions at a joint, for instance, slipping out of the ball of one bone from the socket of another bone into which it is fitted. Dislocation is accompanied by pulling or even tearing of the ligaments. Dislocation also tends to become chronic.

(v) **Slipped disc :** Slipped disc is a displacement of vertebrae and the intervertebral fibrocartilage disc from their normal position. It may result from mechanical injury or defects of ligaments holding the vertebrae together.

(vi) **Fracture :** Fracture is a break of a bone. Fracture occurs rarely in children. The bones of children have a large quantity of organic matter and are, therefore, very flexible and less likely to break. With advancing age, mineral matter (calcium phosphate) is deposited in the bones. This decreases the organic matter, making the bones hard and brittle. Thus, old people are more liable to fracture of bones. Bones fractures are of many types –

(a) **Green-stick fracture :** Fracture in which the bone is partially bent & partially broken, as when a greenstick breaks, occurs only in children.

(b) **Simple or complete fracture :** Bone breaks completely into two parts which remain close to each other.

(c) **Comminuted fracture :** Bone breaks into more than two pieces (smaller fragments between two main fragment,

(d) **Compound fracture :** Bone breaks completely but a fragment pierces out through the skin.

(e) **Evulsive fracture :** A small piece breaks off fully from the bone but remains attached to the ligament. Fractures need surgical treatment for healing and should be promptly and properly attended to.

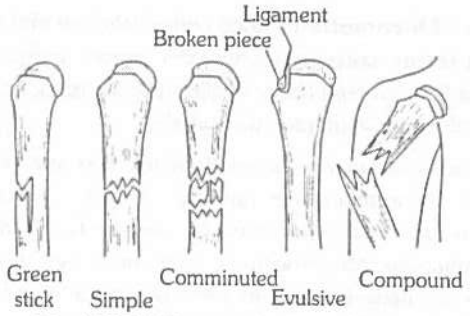

Fig : 5.5-33 Types of bone fracture

(vii) **Bursitis :** Bursitis in inflammation of the bursae present in the joints. It is caused by physical injury or constant pressure on a single joint for a long time.

(viii) **Osteomyelitis :** It is the inflammation of bone due to pus producing organism. It may remain localised or spread inside involving various parts including bone marrow.

Body muscles

In the body of all the multicellular animals muscles are found. The movement of the body takes place by these muscles. If the muscles become weak, the functioning of the body become difficult. The muscles are capable of contraction and relaxation, hence these are elastic.

A muscle can pull a part of the body by its contraction (shortening). It cannot push that part by relaxation (elongation). Hence, the muscles are typically arranged in antagonistic (opposing) pairs, one muscle moves a body part in one direction by its contraction and the other muscle moves that part in the opposite direction by its contraction. Of course, when one muscle contracts, its opposing muscle relaxes. The principle of antagonistic muscles is true of both vertebrate as well as invertebrate muscles. Animal movements depend upon interaction of muscles and skeleton.

(1) **Action of body muscles :** As mentioned above, the body muscles are arranged in antagonistic (opposing) pairs. One muscle of a pair moves a body part in one direction and the other in the opposite direction. For example, the muscle named biceps brings the forearm toward the upper arm, and the muscle called the triceps moves the forearm away from the upper arm. When biceps contracts to cause movement, the triceps relaxes to allow that movement to occur and vice versa. Similar pairs of opposing flexor and extensor muscles occur at the wrist, ankle and knee. The type of movement that results from the contraction of a muscle depends entirely upon the way the muscle is attached to the levers of the skeleton.

(2) **Classification of body muscles :** According to the type of motion they cause, the muscles are divided into the following types. The muscles that act together to produce a movement are called synergists and the muscle that act in opposition to each other are antagonists. The muscles that act most powerfully during any given movements are called prime movers.

(i) **Flexor and Extensor :** Muscles that bend one part over another joint is called flexor. Extensor muscle is antagonist of flexor muscle. The contraction of an extensor extends a joint by pulling one of the articulating bone apart from another.

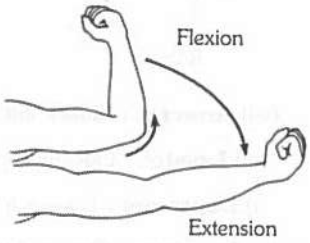

(ii) **Pronator and Supinator :** The contraction of a pronator rotates the forearm to turn the palm downward or backward. Supinator is antagonist of pronator. A supinator contracts to rotate the forearm and thus to make palm face upward or forward.

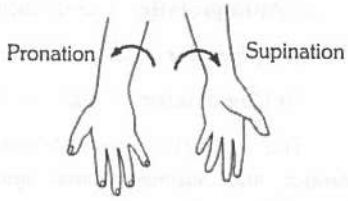

(iii) **Abductor and Adductor :** An abductor contracts to draw a bone away from the body midline. Muscle that brings the limb away from midline is called abductor. An adductor draws a bone towards the body midline. Muscles that brings the limb towards midline is called adductor. Abductor muscle is antagonist of adductor muscle. Abduction is elevation and adduction is depression.

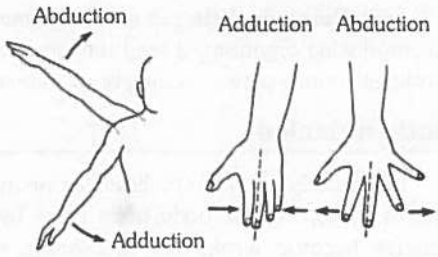

(iv) **Protractor and Retractor :** Protractor muscle pulls the lower jaw, tongue and the head forward. Retraction is opposite to protraction. Retractor muscle draws the lower jaw, tongue and the head backward.

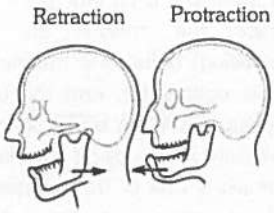

(v) **Inversion and Eversion :** Turning of feet so that the soles face one another in inversion. Eversion is the opposite of inversion. In this movement, the soles of the feet face laterally.

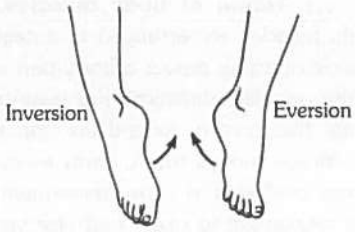

(vi) **Rotation :** Rotation is a term that indicates the partial revolving of a body part on the part's long axis.

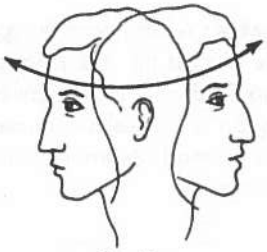
Rotation

Circumduction

(vii) **Arrector :** Raises hairs of skin.

(viii) **Levator :** Elevates a part of body.

(ix) **Depressor :** Lowers a part of body.

(x) **Agonistic :** Opposed in action by another muscle.

(xi) **Antagonistic :** Counteracts the action of another muscle.

(xii) **Sphincter :** Closes a natural orifice or passage.

(xiii) **Constrictor :** Causes constriction or squeezing.

The adductor and abductor, elevator and depressor, pronator and supinator, and sphincters and dilators are all antagonistic muscles.

Important muscles

Table : 5.5-5 In man total no. of muscles : 639 muscles

Biceps and Triceps	Arm
Gastrocnemius	Shank of leg
Gluteimaximus	Buttock muscles
Oblique	Eye muscles
Rectus	Eye muscles
Maxillaries	Upper jaw
Pectoralis Major	Chest
Pectoralis Minor	Chest
Mandibularis	Muscle of lower jaw
Latissisus dorsi	Shoulder muscle
External oblique	Lower abdomen
Internal oblique	Lower abdomen
Transversus	Lower abdomen
Rectus abdominis	Lower abdomen
Stapedial muscle / arrector pilli	Smallest muscle
Sartorius femoris	Longest muscle
Gluteus maximus	Largest muscle

Movement and Locomotion

Movement is one of the most important characteristics of living organisms. Nonliving objects do not move. If nonliving objects show movement, that is always due to some external force. For example, the cart is moved by the horse and the fan revolves by the energy of electric current. The movement of a nonliving object is, therefore induced (due to external force) while the movement of living things are autonomic (self sustained). Study of movement is called kinesiology (*G. Kinein* = to move, *Logos* = study). The movement of living systems are thus autonomic or active, that is effected by the organisms themselves without external influences. On the other hand the movement of nonliving systems are induced or passive, *i.e.*, made to occur by external forces. Movement of animals are two main types muscular and non muscular.

(1) **Muscular movement :** Muscular movement are found in the majority of animals brought about by sliding of myofilaments. Muscular movement are further divide into two kinds – Locomotion and movement of body parts.

(i) **Locomotion (locus = place + moveo = to move) :** Locomotion is the movement of an animal as a whole from one place to another.

Types of locomotion : Locomotion takes several forms such as walking (man), creeping (earthworm, lizard), cursorial (Horse, flightless birds), hopping (frog, rabbit), running (dog, horse), flying (insects, birds) and swimming (fish, whale).

Animals have suitable adaptations for their specific mode of locomotion. Adaptations for running, hopping, swimming and flying are respectively called cursorial, saltatorials, natatorial, and volant adaptations. Morphogenetic movement, *i.e.*, the streaming of cells in the early embryo to form tissues or organs, may be considered a form of locomotion.

UNIVERSAL BOOK DEPOT 1960

Advantage of locomotion : Locomotion is helpful for animals as escape from predators, search of shelter, food and water, shift to favourable environment, reproduction, collect materials for nest building, locate suitable area for breeding and dispersal to new location. All forms of locomotion require energy to overcome two forces that tend to keep the animals stationary. These are friction and gravity.

(a) **Swimming :** Water is a much denser medium than air so body modified for swimming in the form of buoyancy, fusiform body etc. Mode of swimming varies in animals. Fishes swim by moving their body and tail from side to side. Whales and dolphins swim by undulating their body and tail up and down. Insects and 4-legged vertebrates use their legs as oars to push against the water. Cuttle fish and squid are jet-propelled, taking in water and squirting it out in bursts.

(b) **Locomotion on land :** For walking, running, hopping and crawling on land, animal expends energy body to prevent falling down and move forward against gravity. Powerful muscles and strong skeletal support are more important for moving on land than a streamlined body. Creeping animals have their entire body in contact with the ground. Therefore, they make a considerable effort to overcome friction.

(c) **Flying :** Gravity is a major problem in flight. Wings must produce enough lift to make and keep the animal air-borne against the downward force of gravity.

(2) **Non-Muscular movement :** Besides locomotion and movements of body parts, some of the cells of multicellular animals move like unicellular organisms.

(i) **Ciliary movement :** The cilia present in the trachea, vasa efferentia and oviducts propel by their movements dust particles, sperms and eggs respectively. The cilia of flame cells of flatworms push excretory materials. Ciliary movements in *Planaria* or *Dugesia* also.

(ii) **Flagellar movement :** The flagella of choanocytes (collar cells) of the sponges maintain a regular current of water in the body. The flagella of certain cells of gastrodermis of hydra help in the circulation of food. Sperms move by flagellar movements.

(iii) **Pseudopodial movement :** Leucocytes and macrophages move by pseudopodial movement.

(iv) **Cytoplasmic streaming movement :** Streaming movement of the cytoplasm is called cyclosis. It is observed in most of the cells.

Tips & Tricks

- Calf muscle – Gastrocnemius (Shank muscle).
- Trijection muscle – Deltoid muscle.
- Hamstring muscle – Semi tendinosus, semi membranosus, biceps femoris. In players there is very common over stretching of these muscle.
- Flying muscle – Pectoralis major and minor.
- Strongest muscle – Jaw muscle (Masseter).
- Smiling muscle – Buccalis.
- Fastest muscle – Muscles of upper eye lid.
- Sartorius muscle – Flexion of thigh, knee and its rotation.
- Obturator externus – Rotation of thigh on lateral side.
- Tensor tympani – Connects the malleus to the wall of the tympanic chamber in the ear of mammal.
- Hilton muscle is aryepiglotticus muscle.
- In children the bone are more flexible and brittle because their bone have large quantity of organic substances and little salt.
- Hardest tissue in human body – tooth enamel
- In muscular hypertrophy cells increase in size by synthesizing the length of a myofibril.
- Presence of furcula in birds.
- Calcaneal process forms the heal in rabbit.
- Endoplasmic reticulum or sarcoplasmic reticulum play a major role during muscle contraction, muscle excitement and muscle relaxation.
- In birds, fore limbs are modified into wings.
- Skeleton is absent in jelly fish.
- Urostyle present in caudal region of frog.
- Tail vertebrae of birds form pygostyle.
- Birds has pneumatic bone.
- Six typical vertebrae present in frog.
- Central shaft of a long bone is known as diaphysis.
- Curved bone is structurally designed to absorb the stress of the body weight at several different points so that the stress is evenly distributed.
- Tibio-fibula is the shank bone.
- Joint between skull and atlas which allows nodding movement is called atlanto-occipital joint.
- Sphenoid is called as key stone bone of cranial floor, because it articulates with all other cranial bones.
- Ethmoid bone with cribriform plate with 'crista galli' triangular process. Crista galli serves as point of attachment for meninges that cover the brain.
- The bones common to face and cranium are frontal.
- Dermatocranium of skull comprises of membranous bone.
- Coronoid process is a part of lower jaw in mammalian skull.
- Sella turcica is found in base-sphenoid bone. It is a depression in skull which lodges the pituitary body.
- Amphibian & mammalia has dicondylic skull and reptiles, birds has monocondylic skull.
- Alar process is a part of hyoid apparatus.
- Hammer shaped bone in skull of frog is squamosal.
- Rigor mortis – It is the state of body stiffening after death due to non separation of actin and myosin filaments caused by non-availability of ATP.
- Cori's cycle – It is the passage of lactic acid produced in muscles into liver where 80% of it is changed to glucose/glycogen for continued supply to muscles. The remaining is oxidised.

Ordinary Thinking

Objective Questions

Axial skeleton

1. Bone marrow is largely composed of **[CBSE PMT 1990]**
(a) Periosteum and osteoblast
(b) Adipose tissue and blood vessels
(c) Yellow and elastic tissue
(d) Cartilage and elastic tissue

2. The collar bone is known is **[MP PMT 2012]**
(a) Scapula (b) Coracoid
(c) Stapes (d) Clavicle

3. The bony sockets of the jaws in which the teeth are implanted, are known as
(a) Alveolus (b) Fossae
(c) Dentaries (d) Thecae

4. The type of vertebrae in sub-order ophidia is **[Pb. PMT 1999]**
(a) Amphicoelous (b) Acoelous
(c) Heterocoelous (d) Procoelous

5. Number of cranial nerves in mammal are **[RPMT 1995; KCET 2000; Odisha JEE 2008]**
(a) 10 pairs (b) 8 pairs
(c) 12 pairs (d) 16 pairs

6. Nucleus pulposus is **[AFMC 2004]**
(a) A type of special cell found in myelin sheath of a nerve cell of vertebrate
(b) A depression for pituitary is found in mammalian skull
(c) A large nucleus found in Schwann cells of nerve fibre
(d) A remain of embryonic notochord found in the central portion of inter-vertebral discs of vertebrae of mammals

7. The first vertebra, the atlas by its articulation with axis vertebra facilitates a
(a) Noding movement (b) Sideway movement
(c) Rotatory movement (d) Backward movement

8. The vertebrae in which centrum is absent and transverse process are present is known as
(a) Lumber vertebrae (b) Anterior thoracic
(c) Axis vertebrae (d) Atlas vertebrae

9. The number of vertebrae present in cervical, thoracic, lumbar, sacral and coccyx regions respectively are **[NCERT; MH CET 2000; BHU 2001; Kerala PMT 2003, 06; HP PMT 2005; Odisha JEE 2008; AFMC 2008]**
(a) 12, 7, 5, 1, 1 (b) 1, 7, 5, 12, 1
(c) 7, 5, 1, 12, 1 (d) 7, 12, 5, 1, 1
(e) 5, 12, 7, 1, 1

10. Which one of the following items gives its correct total number **[CBSE PMT 2008]**
(a) Types of diabetes – 3
(b) Cervical vertebrae in humans – 8
(c) Floating ribs in humans – 4
(d) Amino acids found in proteins – 16

11. Find out the correct order of number of bones in the parts of skull such as cranial bone, facial bone, hyoid bone and middle ear bone respectively **[Kerala PMT 2007]**
(a) 14, 8, 1 and 6 (b) 6, 8, 14 and 1
(c) 14, 8, 6 and 1 (d) 8, 6, 14 and 1
(e) 8, 14, 1 and 6

12. The number of vertebrae in rabbit is
(a) 40 (b) 33
(c) 44 (d) 46

13. Lumbar vertebra are found in **[CPMT 2005]**
(a) Neck region (b) Abdominal region
(c) Hip region (d) Thorax

14. The skull of a bird is **[Pb. PMT 1999]**
(a) Dicondylic (b) Monocondylic
(c) Amphicondylic (d) None of these

15. The opening at the base of the skull for the spinal cord is called **[CMC Vellore 1993; RPMT 1995; CPMT 2010]**
(a) Foramen Magnum (b) Foramen of Monro
(c) Obturator foramen (d) Foramen of Magendie

16. The 8th and 9th ribs are known as false ribs because their external portions are attached to **[CPMT 1992]**
(a) Xiphisternum (b) Costa of 7th rib
(c) They have no costa (d) They are not true ribs

17. Which one is not cranial bone **[GUJCET 2015]**
(a) Frontal (b) Zygometic
(c) Temporal (d) Sphenoid

18. Thoracic cage in rabbit is made up of **[CPMT 2009]**
(a) Ribs, vertebral column and diaphragm
(b) Ribs, diaphragm and sternum
(c) Vertebral column, diaphragm and sternum
(d) Ribs, vertebral column & sternum

19. In the pelvic girdle of man A, B, C, D and E respectively represents **[Kerala PMT 2008]**

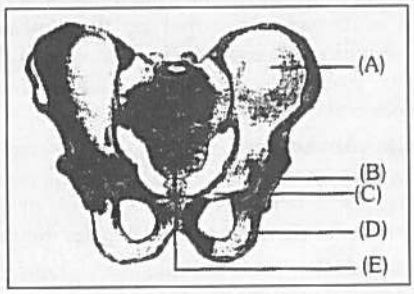

(a) A – pubis, B – acetabulum, C – ilium, D – ischium, E – pubic symphysis
(b) A – ilium, B – acetabulum, C – pubis, D – ischium, E – pubic symphysis
(c) A – ischium, B – acetabulum, C – pubis, D – ilium, E – pubic symphysis
(d) A – ilium, B – pubis, C – acetabulum, D – pubic symphysis, E – ischium
(e) A – ilium, B – acetabulum, C – pubic symphysis, D – ischium, E – pubis

20. The vertebrae in birds are mostly **[CBSE PMT 2000; MH CET 2001]**
(a) Procoelous (b) Amphicoelous
(c) Opisthocoelous (d) Heterocoelous

21. Vertebral formula for human beings is **[Kerala PMT 2006]**
(a) $C_5T_{12}L_7S_5C_{3-5} = 33-35$ (b) $C_7T_{12}L_5S_5C_{3-5} = 33-35$
(c) $C_5T_{10}L_5S_5C_{3-5} = 33$ (d) $C_7T_{10}L_5S_5C_{3-5} = 33$

22. Centrum of man is
(a) Procoelus (b) Amphicoelus
(c) Amphiplateus (d) Ophisthocoelous

UNIVERSAL BOOK DEPOT 1960

23. Long neck of camel is due to **[BHU 1995; CPMT 1995]**
(a) Increase in length of cervical vertebra
(b) Due to bony plate between two vertebra
(c) Due to muscle in between two vertebra
(d) None of the above

24. Sella turcica is a
(a) Covering of kidney
(b) Covering of testis
(c) Depression in brain
(d) Depression in skull which lodges the pituitary body

25. In which bone the chondrocytes are replaced by osteocytes
(a) Maxilla (b) Nasal
(c) Dentary (d) Vomer

26. Which one of the following is the correct description of a certain part of a normal human skeleton **[CBSE PMT (Mains) 2010]**
(a) Parietal bone and the temporal bone of the skull are joined by fibrous joint
(b) First vertebra is axis which articulates with the occipital condyles
(c) The 9th and 10th pairs of ribs are called the floating ribs
(d) Glenoid cavity is a depression to which the thigh bone articulates

27. The number of floating ribs in human body is **[CBSE PMT 1995, 2007; AFMC 2000]**
(a) 6 pairs (b) 3 pairs
(c) 5 pairs (d) 2 pairs

28. Centrum of 8th vertebra of frog is **[DUMET 2009]**
(a) Amphiplatyon (b) Procoelous
(c) Amphicoelous (d) Opisthocoelous

29. In the first two or three lumbar vertebrae there is a small median process below the centrum, this is called
(a) Pre-zygapophysis (b) Post-zygapophysis
(c) Hypapophysis (d) Neural spine

30. In the diagram of section of Hyaline cartilage, the different parts have been indicated by alphabets; choose the answer in which these alphabets correctly match with the parts they indicate **[KCET 2004]**

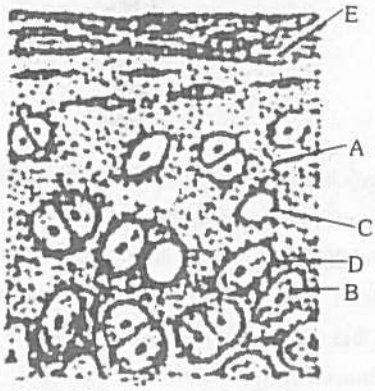

(a) A = perichondrium B= Chondrocyte C= Lacuna D= Capsular matrix E= Chondrin
(b) A= Capsular matrix B= Chondrocyte C= Lacuna D= Perichondrium E= Chondrin
(c) A= Chondrin B= Chondrocyte C= Lacuna D= Capsular matrix E= Perichondrium
(d) A= Chondrin B= Lacuna C= Chondrocyte D= Capsular matrix D= Perichondrium

31. Bone related to skull is **[CBSE PMT 2000]**
(a) Atlas (b) Caracoid
(c) Artenoid (d) Pterygoid

32. What is correct about human body **[MP PMT 1993]**
(a) There are 5 vertebra in the neck
(b) Brain box is made up of 4 bones
(c) There are 15 pairs of ribs
(d) There are 12 thoracic vertebra

33. In mammals (rabbit), the zygomatic arch is formed by **[CPMT 1998]**
(a) Maxilla, premaxilla and squamosal
(b) Periotic, jugal and palatine
(c) Maxilla, squamosal and jugal
(d) Jugal, maxilla and periotic

34. A vertebra has a convexity both in front and behind it. It is called **[AFMC 1997; MH CET 2002; BHU 2012]**
(a) Procoelous (b) Amphicoelous
(c) Acoelous (d) Amphiplatyon

35. The last two pairs of ribs are named floating ribs because
(a) Their sternal parts are attached to the sternum directly
(b) Their sternal parts are attached on the 7th pair of ribs
(c) Their sternal parts remain free and do not even reach the sternum
(d) They float in the body cavity

36. Special fibrous joint occuring exclusively in skull which is the tightest type of joint is **[NCERT; CBSE PMT 1993]**
(a) Suspensorium (b) Suspensory ligament
(c) Suture (d) Occipital

37. The vertebrae which bears the whole weight of the skull is **[CBSE PMT 1993]**
(a) Axis (b) Sacral
(c) Cervical (d) Atlas

38. The parasphenoid bone in frog forms **[CPMT 2004]**
(a) Base of cranium
(b) Floor of cranium
(c) Dorsal side of cranium
(d) Dorsolateral side of cranium

39. How many ribs are present in human beings **[CPMT 1994; HP PMT 2005]**
(a) 6 pairs (b) 9 pairs
(c) 12 pairs (d) 15 pairs

40. Axis vertebra of a mammal differs from atlas in **[CPMT 1993; MP PMT 1994]**
(a) Absence of centrum
(b) Presence of centrum
(c) Presence of central canal
(d) Presence of odontoid process

41. Number of bones in skull is **[MP PMT 2007]**
(a) 26 (b) 28
(c) 107 (d) 29

42. In human beings the cranium is formed by **[AIIMS 2000; MHCET 2000; AMU (Med.) 2010]**
(a) Eight bones of which two are paired
(b) Fourteen bones of which six are paired
(c) Ten bones of which two are paired
(d) Twelve bones of which four are paired

43. Which of the following is unpaired bone
(a) Premaxilla (b) Pro-otics
(c) Sphenethmoid (d) Pterygoid

44. In man the axial skeleton is made up of
(a) 80 bones (b) 100 bones
(c) 103 bones (d) 106 bones

45. The number of bones in half of the lower jaw of man is
(a) 1 (b) 4
(c) 6 (d) 8

46. In man the thoracic basket is composed of **[MP PMT 2002, 06]**
(a) Ribs and thoracic vertebrae
(b) Ribs and sternum
(c) Ribs, sternum and vertebrae
(d) Ribs, sternum and thoracic vertebrae

47. Innominate is a **[CPMT 2009]**
(a) Nerve
(b) Muscle
(c) Animal
(d) A Part of skeleton and anartcry

48. Tongue bone is
(a) Hyoid bone (b) Maxillary
(c) Dentary (d) Quadrato-jugal

49. Human vertebral column consists of 33 vertebrae and _____ bones **[CPMT 1992; BHU 2012]**
(a) 33 (b) 26
(c) 27 (d) 29

50. Cervical vertebrae are located in **[HP PMT 2005]**
(a) Thoracic region (b) Abdominal region
(c) Neck region (d) Lumbar region

51. The number of cervical vertebrae in camels is **[CBSE PMT 2002]**
(a) Same as that in rabbit (b) Same as that in frog
(c) Less than that in giraffe (d) More than that in horse

52. The major function of the intervertebral discs is to **[DUMET 2010]**
(a) Absorb shock
(b) String the vertebrae together
(c) Prevent injuries
(d) Prevent hyperextension

53. Out of 'X' pairs of ribs in humans only 'Y' pairs are true ribs. Select the option that correctly represents values of X and Y and provides their explanation **[NEET 2017]**

(a)	X=12, Y=7	True ribs are attached dorsally to vertebral column and ventrally to the sternum
(b)	X=12, Y=5	True ribs are attached dorsally to vertebral column and sternum on the two ends
(c)	X=24, Y=7	True ribs are dorsally attached to vertebral column but are free on ventral side
(d)	X=24, Y=12	True ribs are dorsally attached to vertebral column but are free on ventral side

Appendicular skeleton

1. In rabbit radius and ulna are **[MP PMT 1992]**
(a) Completely fused together
(b) Completely separated
(c) Fused in middle and separated at both the ends
(d) Separated but united at both the ends

2. A shallow depression in the scapula which receives the head of the upper arm bone is known as the **[NCERT; CBSE PMT 1993; AIPMT (Cancelled) 2015]**

Or

Which one of the following component is the part of pectoral girdle **[CBSE PMT 1994; MP PMT 1994; DPMT 2007]**
(a) Acetabulum (b) Neural arch
(c) Glenoid cavity (d) None of the above

3. Patella, the knee cap is the example of **[NCERT; MP PMT 1996, 2007; BVP 2001; AIIMS 2003; Pb. PMT 2004]**
(a) Cartilage gland (b) Replacing bone
(c) Sesamoid bone (d) None of the above

4. The protein present in the bones is known as **[CBSE PMT 1992]**
(a) Chondrin (b) Ossein
(c) Sclero protein (d) Globulin

5. Humerus bone is situated in
(a) Thigh (b) Lower arm
(c) Upper arm (d) Shank

6. Consider the diagram given below **[Kerala PMT 2006]**

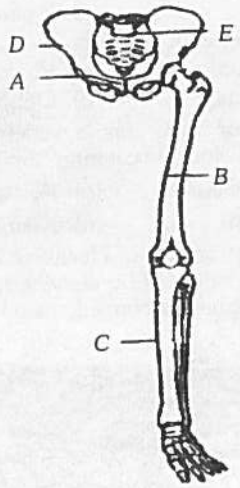

Parts labelled as 'A', 'B', 'C', 'D', and 'E' respectively indicate
(a) Femur, Ilium, Tibia, Pubis and Sacrum
(b) Pubis, Tibia, Femur, Ilium and Sacrum
(c) Ilium, Femur, Tibia, Pubis and Sacrum
(d) Tibia, Pubis, Femur, Ilium and Sacrum
(e) Pubis, Femur, Tibia, Ilium and Sacrum

7. Symphysis contains **[AFMC 2012]**
(a) Hyaline cartilage
(b) Fibrous cartilage
(c) Calcified cartilage
(d) None of these

8. Outer covering of cartilage is **[DPMT 1993; WB JEE 2010]**
(a) Perichondrium (b) Periosteum
(c) Endo-osteum (d) Peritonium

9. Which option is correct for the region labelled as a, b, c and d in the given diagram **[NCERT; GUJCET 2014]**

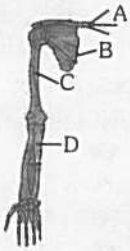

(a) A – Clavicle, B – Scapula, C – Humerus, D – Ulna
(b) A – Scapula, B – Clavicle, C – Humerus, D – Ulna
(c) A – Clavicle, B – Ulna, C – Radius, D – Humerus
(d) A – Clavicle, B – Glenoid cavity, C – Radius, D – Ulna

10. The longest bone of the human body is **[NCERT; Kerala PMT 2009]**

(a) Humerus (b) Tibia
(c) Vertebra (d) Femur
(e) Incus

11. Olecranon fossa is present over **[MH CET 2004]**

(a) Scapula (b) Ulna
(c) Radius (d) Humerus

12. Synsacrum of fowl is consist of about **[BHU 2004]**

(a) 29 vertebrae (b) 3 vertebrae
(c) 16 vertebrae (d) Single vertebrae

13. The pelvic girdle of birds is attached to a complex structure formed by the fusion of last thoracic, all lumbar and first five caudal vertebra. This structure is called **[MP PMT 1993]**

Or

In birds, some of the vertebrae are fused to form **[MHCET 2001; CBSE PMT 2001]**

(a) Synsacrum (b) Symphysis
(c) Synkaryon (d) Sympelvis

14. Given below is a diagram of the left human hindlimb as seen from front. It has certain mistakes in labeling. Two of the wrongly labelled bones are **[AIIMS 2005]**

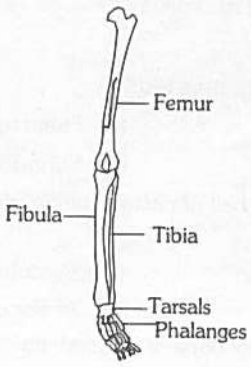

(a) Tibia and tarsals (b) Femur and fibula
(c) Fibula and phalanges (d) Tarsals and femur

15. Consider the following diagram. Identify A, B, C and D **[NCERT]**

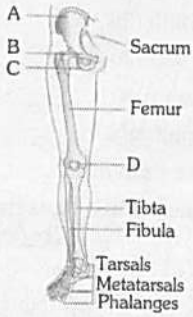

(a) A - Ilium, B - Pubis, C - Ischium, D - Patella
(b) A - Ilium, B - Pubis, C - Patella, D - Ischium
(c) A - Ischium, B - Pubis, C - Ilium, D - Patella
(d) A - Pubis, B - Ilium, C - Ischium, D – Patella

16. Choose the correct option regarding a normal human

A. The skull is dicondylic
B. Metacarpals are five in numbers
C. Patella is a cup-shaped bone covering the knee dorsally
D. Scapula is a large triangular flat bone, situated on the ventral side of the thorax
E. The pelvic girdle has two coxal bones

[Kerala PMT 2012]

(a) A and E alone are wrong (b) A and B alone are wrong
(c) B and E alone are wrong (d) C and D alone are wrong
(e) E alone is wrong

17. The pectoral and pelvic girdles and the bones of limb form **[DPMT 1993; MHCET 2000]**

(a) Axial skeleton (b) Appendicular skeleton
(c) Visceral skeleton (d) Outer skeleton

18. What will happen if a bone is kept in 10% *KOH* solution for 3 days

(a) Remain unchanged (b) Dissolved
(c) Become soft and elastic (d) Break

19. The canal seen in the bone of mammals are **[AFMC 1993]**

(a) Haversian canals only
(b) Volkmann's canals only
(c) Haversian and Volkmann's canals
(d) Canal of Schlemm

20. Number of bones in human body is **[NCERT; CMC Vellore 1993; Pb. PMT 2000; JIPMER 2002]**

(a) 260 (b) 206
(c) 306 (d) 203

21. The total number of bones in your right arm is **[NCERT; AFMC 2004]**

Or

Total number of bones in the hind limb of a man is **[NCERT; CBSE PMT 1998]**

(a) 30 (b) 32
(c) 35 (d) 40

22. Scapula is a large triangular flat bone situated in the dorsal part of the thorax between **[Kerala PMT 2011]**
(a) The second and fifth ribs
(b) The second and seventh ribs
(c) The third and sixth ribs
(d) The third and eighth ribs
(e) The fourth and seventh ribs

23. An acromian process is characteristically found in rabbit/mammals in **[NCERT; MP PMT 1994, 95; CBSE PMT 2005]**
(a) Pelvic girdle (b) Pectoral girdle
(c) Skull (d) Sternum

24. The matrix of bone and cartilage can be distinguished by the presence of **[Odisha JEE 2010]**
(a) Haversian canal (b) Lacuna
(c) Chromatophores (d) Adipose cells

25. What is the difference between the bone of rabbit and that of frog **[CPMT 1996]**
(a) In the bone of rabbit haversian canal is found
(b) Yellow marrow is found
(c) Osteocytes are of different types
(d) Bone of frog is spongy

26. Acetabulum is present in **[NCERT; CPMT 2010]**
(a) Pelvic girdle of rabbit (b) Pectoral girdle of rabbit
(c) Both (a) and (b) (d) None of these

27. Ends of long bones are covered with **[MP PMT 1994]**
(a) Cartilage (b) Muscles
(c) Ligaments (d) Blood cells

28. Olecranon process is found in **[MP PMT 1994]**
(a) Proximal end of ulna (b) Distal end of ulna
(c) Proximal end of tibia (d) Proximal end of humerus

29. Which of the following is absent in the segment of cockroach's leg **[DPMT 2004]**
(a) Fibula (b) Coxa
(c) Tibia (d) Femur

30. Three of the following pairs of the human skeletal parts are correctly matched with their respective inclusive skeletal category and one pair is not matched. Identify the non-matching pair **[CBSE PMT (Mains) 2011]**

	Pairs of skeletal parts	Category
(a)	Humerus and ulna	Appendicular skeleton
(b)	Malleus and stapes	Ear ossicles
(c)	Sternum and Ribs	Axial skeleton
(d)	Clavicle and Glenoid cavity	Pelvic girdle

31. Astragalus and calcaneum are present in **[Pb. PMT 1999; AIIMS 2001]**
(a) Fore limb (b) Hind limb
(c) Scapula (d) Clavicle

32. Deltoid ridge is found in which one of the following bones **[RPMT 1999, 2005; CPMT 2002; DPMT 2004]**
(a) Radius (b) Tibia
(c) Femur (d) Humerus

33. Pelvic girdle of rabbit consist of **[NCERT; CPMT 2002; RPMT 2005]**

Or

The coxal of the pelvic girdle is formed by the fusion of **[CBSE PMT 2009; Kerala PMT 2011]**

Or

In mammals, each half of pelvic girdle or obturator foramen in pelvic girdle is formed by **[MP PMT 1998, 2013; PET Pharmacy 2013]**
(a) Ilium, ischium and pubis
(b) Ilium, ischium and coracoid
(c) Coracoid, scapula and clavicle
(d) Ilium, coracoid and scapula

34. Pectoral girdle constitute **[AFMC 2010]**
(a) Scapula and Clavicle
(b) Radius and Ulna
(c) Ilium and Ischium
(d) Maxilla and mandible

35. The sigmoid notch is present in
(a) Femur (b) Tibio-fibula
(c) Humerus (d) Ulna

36. Presence of furcula is a characteristic feature of
(a) Frogs (b) Reptiles
(c) Birds (d) Mammals

37. In children the bones are more flexible and brittle because their bones have
(a) Large quantity of salts and little organic substances
(b) Large quantity of organic substances and little salts
(c) Well developed Haversian system
(d) Large number of osteoblasts

38. Ankle bones have 6 tarsals and arranged in three rows then 1st row have **[CPMT 1994]**
(a) Astragalus and calcaneum
(b) Pterygoid and astragalus
(c) Pterygoid and calcaneum
(d) None of these

39. Triceps muscle joins ulna with
(a) Radius (b) Humerus
(c) Phallanges (d) Suprascapula

40. In mammals each half of pectoral girdle consists of **[MP PMT 1998]**
(a) Supra scapula (b) Scapula
(c) Coracoid (d) All the above

41. Innominate or hip bone is formed by the fusion of how many bones **[NCERT]**
(a) 2 (b) 3
(c) 4 (d) 5

UNIVERSAL BOOK DEPOT 1960

42. Haversian canals are found in
[AFMC 1997; MP PMT 1997, 2012; BHU 2000; DPMT 2003; MHCET 2003; BVP 2004; CPMT 2010]
(a) Spinal cord (b) Brain
(c) Long bones (d) Sponge

43. Phallangeal formula of hand of man is **[NCERT]**
(a) 1, 2, 2, 2, 2 (b) 2, 1, 1, 1, 1
(c) 2, 3, 3, 3, 3 (d) 2, 3, 3, 2, 2

44. Structure responsible for formation of sigmoid notch is
[CPMT 2005]
(a) Olecranon process of humerus
(b) Olecranon process of femur
(c) Olecranon process of radius ulna
(d) Olecranon process of tibia fibula

45. Old people are, more liable to fracture of their bones because
(a) Bones become soft and elastic
(b) Bones become hard and brittle
(c) Bones contain large quantity of organic matter
(d) None of the above

Joints

1. The gliding joints are important for gliding movements. One example of such a joint is between the
[MP PMT 1992; BVP 2003]
(a) Zygapophysis of adjacent vertebrae
(b) Humerus and the glenoid cavity
(c) Occipital condyle and odontoid process
(d) Femur and tibio-fibula

2. An example of synovial joint is found between
[MP PMT 1992]
(a) Two vertebrae (b) Two skull bones
(c) Humerus and ulna (d) Tail vertebrae

3. The example of pivot joint is **[DUMET 2010]**
(a) Hip joints
(b) Metacarpophalangeal joints
(c) Ankle joints
(d) Radioulnar joints

4. Elbow joint is an example of **[CBSE PMT 2009]**
(a) Pivot joint
(b) Hinge joint
(c) Gliding joint
(d) Ball and socket joint

5. Hinge joint is present between **[DPMT 1993; CPMT 1994, 96; MP PMT 1994, 2006, 07, 12; BHU 2000; MH CET 2003; Pb. PMT 2004]**
(a) Humerus and pectoral girdle
(b) Femur and acetabulum
(c) Humerus and radio-ulna
(d) Femur and pelvic girdle

6. Match the following and choose the correct option

Types of synovial joints		Bones involved	
A.	Ball and socket	1.	Carpal and metacarpal of thumb
B.	Hinge	2.	Atlas and axis
C.	Pivot	3.	Frontal and parietal
D.	Saddle	4.	Knee
		5.	Humerus and pectoral girdle

[NCERT; CBSE PMT 1999; Kerala PMT 2010; Odisha JEE 2010]
(a) A-5, B-4, C-2, D-1 (b) A-1, B-3, C-4, D-5
(c) A-5, B-4, C-3, D-1 (d) A-1, B-2, C-5, D-4
(e) A-2, B-5, C-4, D-1

7. The joint between the lower jaw and the skull is
(a) Gliding (b) Hinge
(c) Perfect joint (d) Saddle joint

8. Ball and socket joints can be seen in
[MP PMT 1993; J & K CET 2002; Odisha JEE 2011]
(a) Wrist (b) Fingers
(c) Neck (d) Shoulders

9. The type of joint between the human skull bones is
[CBSE PMT 1994; BHU 1999]
(a) Synarthrodial joint (b) Synovial joint
(c) Cartilaginous joint (d) Fibrous joint

10. Which cartilage is present at the joints of long bones
[MP PMT 1998; CBSE PMT 2002; CPMT 2009]
(a) Calcified (b) Hyaline
(c) Elastic (d) Fibrous

11. Which one of the following pairs of structures is correctly matched with their correct description
[CBSE PMT (Mains) 2010]

	Structures	Description
(a)	Tibia and fibula	Both form parts of knee joint
(b)	Cartilage and cornea	No blood supply but do require oxygen for respiratory need
(c)	Shoulder joint and elbow joint	Ball and socket type of joint
(d)	Premolars and molars	20 in all and 3— rooted

12. When the head of humerus fits into glenoid cavity, joint is
(a) Ball and socket joint (b) Hinge joint
(c) Pivot joint (d) Saddle joint

13. An all out sprint can not continue for more than 40 seconds because **[Odisha JEE 2004]**
(a) Run out of oxygen (b) Accumulation of creatine
(c) Muscles collapse (d) All of these

14. Select the correct matching of the type of the joint with the example in human skeletal system **[MP PMT 2003; CBSE PMT 2014]**

Type of joint		Example
(a) Hinge joint	-	Between humerus and pectoral girdle
(b) Gliding joint	-	Between carpals
(c) Cartilaginous joint	-	Between frontal and parietal
(d) Pivot joint	-	Between third and fourth cervical vertebrae

15. Which of the following joints would allow no movement **[AIPMT 2015]**
(a) Cartilaginous joint (b) Synovial joint
(c) Ball and socket joint (d) Fibrous joint

16. The ankle, knee and elbow joints are **[NCERT; DPMT 2006; J & K CET 2010]**
(a) Synovial joints (b) Hinge joints
(c) Pivot joints (d) Ellipsoid Joints

17. Joint between femur and pelvic girdle is **[CPMT 1995; CBSE PMT 2001; MH CET 2003]**
Or
Joint between femur and acetabulum is known as **[CPMT 1996]**
(a) Pivotal (b) Ball and socket
(c) Hinge (d) Saddle

18. Achilles tendon is associated with **[BHU 2004]**
(a) Gluteus muscle (b) Hamstring muscle
(c) Quadriceps muscle (d) Gastrocnemius muscle

19. Joint between femur and tibio–fibula is **[CPMT 1996]**
(a) Hinge joint (b) Saddle joint
(c) Pivot joint (d) Imperfect joint

20. .....acts as a shock absorber to cushion when tibia and femur came together **[Odisha JEE 2005]**
(a) Ligament (b) Cartilage
(c) Tendon (d) Disc

21. The end of long bones are connected to each other by **[CPMT 1992, 93, 98, 2000, 2003; DPMT 1993; MP PMT 1994, 97, 2001, 06; AFMC 1997, 2005; RPMT 1999; J & K CET 2002; BHU 2006]**
(a) Muscles (b) Tendons
(c) Ligaments (d) Cartilage

22. Joint between ribs and sternum is **[CBSE PMT 2000]**
(a) Cartilagenous (b) Angular joint
(c) Fibrous joint (d) Gliding joint

23. Sutural joints are found between **[MP PMT 2000]**
(a) Parietals of skull
(b) Humerus and radio-ulna
(c) Glenoid cavity and pectoral girdle
(d) Thumb and metatarsal

24. Which of the following pairs, is correctly matched **[CBSE PMT 2005]**

(a) Hinge joint	–	Between vertebrae
(b) Gliding joint	–	Between zygapophyses of the successive vertebrae
(c) Cartilaginous joint	–	Skull bones
(d) Fibrous joint	–	Between phalanges

25. Tendon is a structure which connects **[DPMT 1992; CPMT 1993; MP PMT 1999, 2004, 11; BVP 2001; MHCET 2004]**
(a) A bone with another bone
(b) A nerve with a muscle
(c) A muscle with a bone
(d) A muscle with a muscle

26. Synovial joints is **[Odisha JEE 2004]**
(a) Pivot joint (b) Hinge joint
(c) Ball and socket joint (d) All of these

27. The pivot joint between atlas and axis is a type of **[NEET 2017]**
(a) Fibrous joint (b) Cartilaginous joint
(c) Synovial joint (d) Saddle joint

Muscles

1. Sarcolemma is a membrane found over in **[MP PMT 1994]**
(a) Nerve fibre (b) Cardiac muscle
(c) Skeletal muscle fibre (d) Heart

2. Ensheathing of muscles is called **[CPMT 1999; JIMPER 2001]**
(a) Fascia (b) Peritoneum
(c) Ligament (d) Tendon

3. Standing on tip toe is an example of **[DUMET 2009]**
(a) Elevation (b) Flexion
(c) Extension (d) Retraction

4. Action potential in a muscle fibre is
(a) – 90 *mV* (b) – 80 *mV*
(c) 45–50 *mV* (d) 90 *mV*

5. The generation of excitation-contraction coupling involves all the following events except **[WB JEE 2009]**
(a) Generation of end-plate potential
(b) Release of calcium from troponin
(c) Formation of cross-linkages between actin and myosin
(d) Hydrolysis of ATP to ADP

6. See the figure of actin (thin) filaments. Identify A, B and C **[NCERT]**

(a) A - Troponin, B - Tropomyosin, C - F - actin
(b) A - Troponin, B - Tropomyosin, C - Myosin
(c) A - Troponin, B - Myosin, C - F - Tropomyosin
(d) A - Tropomyosin, B - Troponin, C - F – actin

7. The contraction of muscle of shortest duration is seen in
(a) Heart (b) Jaws
(c) Intestine (d) Eyelids

8. 'Gastrocnemius' is a muscle of
(a) Forelimbs (b) Thigh
(c) Shank (d) Abdomen of frog

9. ATPase enzyme needed for muscle contraction is located in **[CBSE PMT 2004]**
Or
The contractile protein of skeletal muscle involving ATPase activity is **[CBSE PMT 1998; 2006]**
(a) Myosin (b) Actin
(c) Actinin (d) Troponin

10. Select the letter from the figure that most appropriately corresponds to the structure

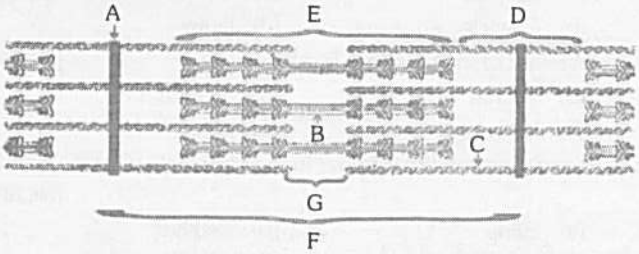

I. A - band
II. I - band
III. Sarcomere
IV. H - zone
V. Myosin
VI. Actin, Troponin, Tropomyosin
VII. Z- line **[NCERT]**

(a) I - E, II - D, III - F, IV - A, V - B, VI - C, VII - G
(b) I - E, II - D, III - F, IV - G, V - C, VI - A, VII - B
(c) I - E, II - D, III - C, IV - G, V - B, VI - A, VII - F
(d) I - E, II - D, III - F, IV - G, V - B, VI - C, VII – A

11. What is sprain **[AIIMS 1993; BHU 1995]**
(a) More pulling of tendon (b) Less pulling of tendon
(c) More pulling of ligament (d) Less pulling of ligament

12. Muscles are red because of the presence of
(a) Myoglobin and mitochondria
(b) Haemoglobin and golgi bodies
(c) Globulin and mitochondria
(d) Protein and lysosome

13. The dark bands in a myofibril are due to overlapping of
(a) Only thick bands
(b) Only thin bands
(c) Both thick and thin bands
(d) None of the above

14. The muscle fatigue occurs due to accumulation of **[CPMT 1995; Manipal 2005; Wardha 2005]**
(a) Pyruvic acid (b) ATP
(c) Lactic acid (d) Eroman CO_2

15. The muscular contraction in which the tension remains the same and the mechanical work is also done is called
(a) Isotonic contraction
(b) Tetanus
(c) Isomeric contraction
(d) Single muscle twitch

16. In a relaxed fibril, *H*–zone, a lighter region of low density can be seen in the centre of

Or

The dark bands (Black bands) of a skeletal muscle are known as
(a) Anisotropic or A–band (b) Isotropic or I–band
(c) *Z*–band (d) Both in *A* and *I*–band

17. The total number of muscles in the body of man is
(a) 409 (b) 439
(c) 539 (d) 639

18. Major protein in the thick filament of skeletal muscle fibre is **[MP PMT 2011]**
(a) Tropomyosin (b) Myosin
(c) Actin (d) Troponin

19. Select the correct statement with respect to disorders of muscles in humans **[NEET (Karnataka) 2013]**
(a) Failure of neuromuscular transmission in myasthenia gravis can prevent normal swallowing
(b) Accumulation of urea and creatine in the joints cause their inflammation
(c) An overdose of vitamin D causes osteoporosis
(d) Rapid contractions of skeletal muscles causes muscle dystrophy

20. Largest number of muscles will be found in **[MP PMT 1993]**
(a) Head (b) Neck
(c) Back (d) Arm

21. Muscles of the heart are **[NCERT; WB JEE 2011]**
(a) Voluntary, striated (b) Voluntary, smooth
(c) Involuntary, striated (d) Involuntar, smooth

22. Cori's cycle operates in
(a) Liver (b) Liver and muscles
(c) Nerve (d) Muscles

23. Contraction of a muscle is caused by **[MP PMT 1994]**
(a) Myosin (b) Actin
(c) ATP (d) Actomyosin

24. The biceps and triceps muscles are found in
(a) Fore arm (b) Shank
(c) Shoulder (d) Lower jaw

25. For the given statement 'X' and 'Y', which option is the correct option

Statement 'X' – Red muscle are also called aerobic muscle

Statement 'Y' – Red muscle possesses large amount of mitochondria which can utilize large amount of oxygen stored in them for ATP production **[GUJCET 2014]**
(a) Statement 'X' and 'Y' are correct and statement 'Y' is incorrect explanation for 'X'
(b) Statement 'X' is correct and 'Y' is incorrect
(c) Statement 'X' is incorrect and 'Y' is correct
(d) Statement 'X' and 'Y' are correct and statement 'Y' is correct explanation for 'X'

26. Ciliary muscles are found in
(a) Diaphragm of a mammal
(b) Eyes of vertebrates
(c) Heart of vertebrates
(d) Stomach of frog

27. The given figure is associated with myosin monomer (meromyosin). Identify A to C **[NCERT; KCET 2015]**

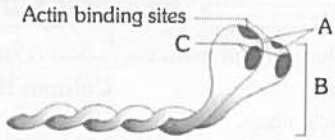

(a) A - cross arm, B - head, C - ATP binding sites
(b) A - head, B - cross arm, C - ATP binding sites
(c) A - head, B - cross arm, C - Ca^{+2} binding sites
(d) A - head, B - cross arm, C - GTP binding sites

28. Electron microscopic studies of the sarcomeres have revealed that during muscle contraction **[MHCET 2003; KCET 2005; NEET (Karnataka) 2013]**
(a) The width of A–band remains constant
(b) The width of the H–zone becomes smaller
(c) The width of I–band increases
(d) The diameter of the fibre increases

29. Latissius dorsi muscles are
(a) Muscles of fore arm (b) Muscles of lower jaw
(c) Muscles of the chest (d) Muscles of the shoulder

30. During muscle contraction **[AMU (Med.) 2005]**
(a) Chemical energy is changed into electrical energy
(b) Chemical energy is changed into mechanical energy
(c) Chemical energy is changed into physical energy
(d) Mechanical energy is changed into chemical energy

31. The H-zone in the skeletal muscle fibre is due to **[NEET 2013]**
(a) Extension of myosin filaments in the central portion of the A-band
(b) The absence of myofibrils in the central portion of A-band
(c) The central gap between myosin filaments in the A-band
(d) The central gap between actin filaments extending through myosin filaments in the A-band

32. Identify the tissue shown in the diagram and match with its characteristics and its location

[NEET (Karnataka) 2013]
(a) Smooth muscles, show branching, found in the walls of the heart
(b) Cardiac muscles, unbranched muscles, found in the walls of the heart
(c) Striated muscles, tapering at both-ends, attached with the bones of the ribs
(d) Skeletal muscle, shows striations and closely attached with the bones of the limbs

NCERT Exemplar Questions

1. Match the following and mark the correct option

Column I	Column II
A. Fast muscle fibres	i. Myoglobin
B. Slow muscle fibres	ii. Lactic acid
C. Actin filament	iii. Contractile unit
D. Sarcomere	iv. I-band

Options **[NCERT]**
(a) A-i, B-ii, C-iv, D-iii (b) A-ii, B-i, C-iii, D-iv
(c) A-ii, B-i, C-iv, D-iii (d) A-iii, B-ii, C-iv, D-i

2. Ribs are attached to **[NCERT]**
(a) Scapula (b) Sternum
(c) Clavicle (d) Ilium

3. ATPase of the muscle is located in **[NCERT]**
(a) Actinin (b) Troponin
(b) Myosin (d) Actin

4. Intervertebral disc is found in the vertebral column of **[NCERT]**
(a) Birds (b) Reptiles
(c) Mammals (d) Amphibians

5. Which one of the following is showing the correct sequential order of vertebrae in the vertebral column of human beings **[NCERT]**
(a) Cervical – lumbar – thoracic – sacral – coccygeal
(b) Cervical – thoracic – sacral – lumbar – coccygeal
(c) Cervical – sacral – thoracic – lumbar – coccygeal
(d) Cervical – thoracic – lumbar – sacral – coccygeal

6. Which one of the following options is incorrect **[NCERT]**
(a) Hinge joint – between Humerus and Pectoral girdle
(b) Pivot joint – between atlas, axis and occipital condyle
(c) Gliding joint – between the carpals
(d) Saddle joint – between carpel and metacarpals of thumb

7. Match the followings and mark the correct option

Column I	Column II
A. Sternum	i. Synovial fluid
B. Glenoid Cavity	ii. Vertebrae
C. Freely movable joint	iii. Pectoral girdle
D. Cartilagenous joint	iv. Flat bones

Options **[NCERT]**
(a) A-ii, B-i, C-iii, D-iv (b) A-iv, B-iii, C-i, D-ii
(c) A-ii, B-i, C-iv, D-iii (d) A-iv, B-i, C-ii, D-iii

8. Macrophages and leucocytes exhibit **[NCERT]**
(a) Ciliary movement (b) Flagellar movement
(c) Amoeboid movement (d) Gliding movement

9. Which one of the following is not a disorder of bone **[NCERT]**
(a) Arthritis (b) Osteoporosis
(c) Rickets (d) Atherosclerosis

10. Which one of the following statement is incorrect **[NCERT]**
(a) Heart muscles are striated and involuntary
(b) The muscles of hands and legs are striated and voluntary
(c) The muscles located in the inner walls of alimentary canal are striated and involuntary
(d) Muscles located in the reproductive tracts are unstriated and involuntary

11. Which one of the following statements is true **[NCERT]**
(a) Head of humerus bone articulates with acetabulum of pectoral girdle
(b) Head of humerus bone articulates with glenoid cavity of pectoral girdle
(c) Head of humerus bone articulates with a cavity called acetabulum of pelvic girdle
(d) Head of humerus bone articulates with a glenoid cavity of pelvic girdle

Critical Thinking

Objective Questions

1. Typically all mammals have seven cervical vertebrae except in **[CBSE PMT 1990]**
   (a) Elephant (b) Man
   (c) Kangaroo (d) Sea cow
2. The membranous areas between the cranial bones of the foetal skull are called **[DUMET 2010]**
   (a) Areolas (b) Foramina
   (c) Sutures (d) Fontanelle
3. Select the correct statement regarding the specific disorder of muscular or skeletal system **[NCERT; CBSE PMT (Pre.) 2012]**
   (a) Muscular dystrophy-age related shortening of muscles
   (b) Osteoporosis-decrease in bone mass and higher chances of fractures with advancing age
   (c) Myasthenia gravis–auto immune disorder which inhibits sliding of myosin filaments
   (d) Gout-inflammation of joints due to extra deposition of calcium
4. Which of the following is not a function of the skeletal system **[AIPMT 2015]**
   (a) Storage of minerals (b) Production of body heat
   (c) Locomotion (d) Production of erythrocytes
5. The zygomatic process in mammals arises from
   (a) Premaxilla (b) Maxilla
   (c) Mandible (d) Squamosal
6. In frog, the vertebra with an anterior convex surface is **[AIIMS 2000; CPMT 2001]**
   (a) Atlas (b) Urostyle
   (c) 8th vertebra (d) 9th vertebra
7. Epiphyseal discs, which are present at the ends of long bones are responsible for **[AIIMS 1993]**
   (a) Bone elongation
   (b) Growth of thickness of the bone
   (c) Remodelling the shape of bone
   (d) Formation of Haversian canal
8. A greater trochanter is found in **[BHU 2002]**
   (a) Femur (b) Humerus
   (c) Ulna (d) Radius
9. The Paget's disease is caused by **[AMU (Med.) 2009]**
   (a) Prolonged deficiency of vitamin D in adults
   (b) Abnormal bone resorption by abnormal osteoclasts
   (c) Excess alkaline phosphatase
   (d) Excess production and abnormal organization of collagen
10. Bone is distinguished from the cartilage by the presence of **[JIPMER 1993; CPMT 1993, 2002]**
    (a) Collagen (b) Blood vessels
    (c) Lymph vessels (d) Haversian canals
11. Which of the following is not found in birds **[AIIMS 1999]**
    (a) Pectoral girdle (b) Pelvic girdle
    (c) Hind limb (d) Fore limb
12. Interphalangeal joints are also called as
    (a) Fixed joints (b) Hinge joints
    (c) Movable joints (d) Straight joints
13. The immediate regeneration of ATP used up during muscle contraction is facilitated by **[AIIMS 1992]**
    (a) Glucose (b) Glycogen
    (c) Lactic acid (d) Creatine phosphate
14. Smallest muscle in the human body **[JIPMER 2002]**
    (a) Sartorius (b) Spinal muscle
    (c) Stapes (d) Stapedius
15. Quadriceps and Gastrocnemius muscle lies in **[MP PMT 2001]**
    (a) Hands (b) Legs
    (c) Shoulder (d) Wrist
16. See the following figure describing muscle contraction

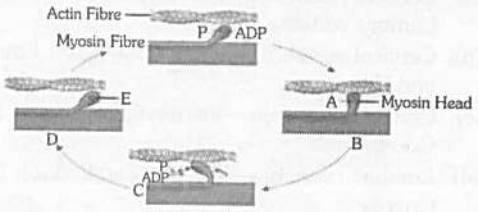

    Identify A, B, C, D and E **[NCERT]**
    (a) A - Cross bridge, B - Cross bridge formation, C - Sliding/ rotation, D - ADP, E - Breaking of cross bridge
    (b) A - Cross bridge, B - Breaking of cross bridge, C - Sliding/ rotation, D - Cross bridge formation, E - AMP
    (c) A - Cross bridge, B - Cross bridge formation, C - Sliding/ rotation, D - Breaking of cross bridge, E - ATP
    (d) A - Cross bridge, B - Cross bridge formation, C - Breaking of cross bridge, D - Sliding (rotation), E - ATP
17. The given figure represents rib cage. Identify A, B and C respectively **[NCERT]**
    (a) Tarsal, ribs, vertebral column
    (b) Scapula, ribs, vertebral column
    (c) Sternum, ribs, vertebral column
    (d) Coccyx, ribs, vertebral column

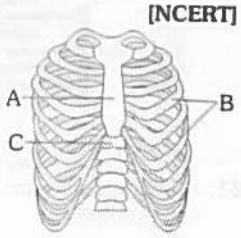

18. Study the diagram given below

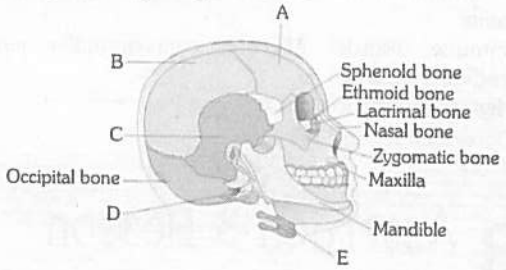

    Parts labelled as A, B, C, D and E respectively represent **[NCERT]**
    (a) Parietal bone, Frontal bone, Temporal bone, Occipital condyle and Hyoid bone
    (b) Frontal bone, Parietal bone, Temporal bone, Hyoid bone and Occipital condyle
    (c) Frontal bone, Temporal bone, Parietal bone, Occipital condyle and Hyoid bone
    (d) Frontal bone, Parietal bone, Temporal bone, Occipital condyle and Hyoid bone

19. The given figure indicates vertebral column of human (right lateral view). Parts labelled as A, B, C and D respectively represent **[NCERT]**

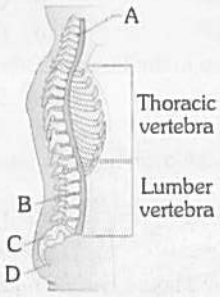

(a) Cervical vertebra, Intervertebral disc, Sacrum and Lumbar vertebra
(b) Cervical vertebra, Intervertebral disc , Lumbar vertebra and Coccyx
(c) Cervical vertebra, Intervertebral disc, Sacrum and Coccyx
(d) Lumbar vertebra, Intervertebral disc, Sacrum and Coccyx

20. Which of the following sarcomeres is labelled correctly **[NCERT]**

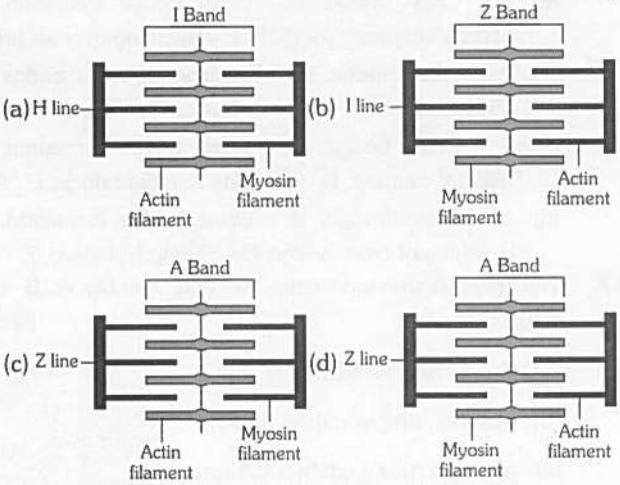

21. Osteoporosis, an age related disease of skeletal system, may occur due to **[NEET (Phase-II) 2016]**
(a) Accumulation of uric acid leading to inflammation of joints
(b) Immune disorder affecting neuromuscular junction leading to fatigue
(c) High concentration of Ca^{++} and Na^{+}
(d) Decreased level of estrogen

AR Assertion & Reason

Read the assertion and reason carefully to mark the correct option out of the options given below :

(a) If both the assertion and the reason are true and the reason is a correct explanation of the assertion
(b) If both the assertion and reason are true but the reason is not a correct explanation of the assertion
(c) If the assertion is true but the reason is false
(d) If both the assertion and reason are false
(e) If the assertion is false but reason is true

1. Assertion : Ball and socket joints are the most mobile joints.
Reason : Synovial fluid is present here.

2. Assertion : Locomotion in *Hydra* is carried out by two types of contractile cells.
Reason : Muscle fibres are lacking in *Hydra*.

3. Assertion : Triceps is said to be an extensor muscle for elbow joint.
Reason : Triceps relaxes durings extension of forearm at the elbow joint.

4. Assertion : Muscle contraction force increases with rise in strength of stimulus.
Reason : This is due to increased contraction of individual muscle fibres with increase in stimulus strength.

Answers

Axial skeleton

1	b	2	d	3	a	4	d	5	c
6	d	7	c	8	d	9	d	10	c
11	e	12	b	13	b	14	b	15	a
16	b	17	b	18	d	19	b	20	d
21	b	22	c	23	b	24	d	25	c
26	a	27	d	28	c	29	c	30	c
31	d	32	d	33	c	34	c	35	c
36	c	37	d	38	b	39	c	40	d
41	b	42	a	43	c	44	a	45	a
46	d	47	d	48	a	49	b	50	c
51	a	52	a	53	a				

Appendicular skeleton

1	d	2	c	3	c	4	b	5	c
6	e	7	b	8	a	9	a	10	d
11	d	12	c	13	a	14	c	15	a
16	d	17	b	18	a	19	c	20	b
21	a	22	b	23	b	24	a	25	a
26	a	27	a	28	a	29	a	30	d
31	b	32	d	33	a	34	a	35	d
36	c	37	b	38	a	39	b	40	d
41	b	42	c	43	c	44	c	45	b

Joints

1	a	2	c	3	d	4	b	5	c
6	a	7	d	8	d	9	a	10	b
11	b	12	a	13	d	14	b	15	d
16	a	17	b	18	d	19	a	20	a
21	c	22	a	23	a	24	b	25	c
26	d	27	c						

Muscles

1	c	2	a	3	a	4	c	5	b
6	a	7	d	8	c	9	a	10	d
11	c	12	a	13	c	14	c	15	a
16	a	17	d	18	b	19	a	20	c
21	c	22	b	23	d	24	a	25	d
26	b	27	b	28	a	29	d	30	b
31	d	32	d						

NCERT Exemplar Questions

1	c	2	b	3	b	4	c	5	d
6	a	7	b	8	c	9	d	10	c
11	b								

Critical Thinking Questions

1	d	2	d	3	b	4	b	5	d
6	d	7	a	8	a	9	b	10	d
11	d	12	b	13	d	14	d	15	b
16	c	17	c	18	d	19	c	20	d
21	d								

Assertion and Reason

1	b	2	a	3	c	4	c		

AS Answers and Solutions

Axial skeleton

4. (d) In the procoelous vertebrae, the anterior surface is concave and posterior surface convex.

14. (b) Since it has a single occipital condyle.

15. (a) The cranial cavity in which the brain is lodged posteriorly opens by foramen magnum. The brain is connected to spinal cord at this foramen.

16. (b) The eighth, ninth and tenth pairs of ribs are called false ribs. They articulate by cartilage with costal cartilage of the seventh rib.

20. (d) Vertebrae of birds are mostly heterocoelous.

21. (b) Cervical vertebrae are 7 in number, thoracic 12 in number, lumbar 5 in number, sacral 5 in number in childhood, they fuse in adults to form a single bone, the sacrum coccygeal vary from 3–5 in number.

23. (b) Long neck of camel is due to bony plates between two vertebra (which are long).

24. (d) *Sella turcica* or 'Turkish saddle' is a depression in the floor of the mammalian skull in the sphenoid (Basi sphenoid) bone in which the pituitary body is lodged.

26. (a) Immovable/fixed/fibrous joint are present between the skull bones. So, between parietal bone and the temporal bone of the skull are joined by fibrous joint.

27. (d) The last two pairs (11th and 12th) of ribs which have no connection with the sternum at all are known as floating ribs.

29. (c) The first two or three lumbar vertebrae has another unpaired additional process, the hypapophysis, which extends downwards from the midventral part of centrum.

31. (d) Pterygoid is short rod shaped bone forming the posterior roof of mouth cavity.

32. (d) Thoracic vertebrae are 12 in number, present in the chest.

34. (c) Acoelous means without cavity on either of its ends. It can be amphiplatyon with both ends flats or amphidicondylar with both ends convex. Procoelous have anterior concavity, amphicoelous has both sides concave.

36. (c) The skull bones fit together by sutures.

37. (d) According to Greek mythology, their one God Atlas supports the earth. If the skull can be considerd as the globe (earth), then first vertebra which bears whole of its weight can be regarded as Atlas. It is named on this basis only.

38. (b) Parasphenoid bone is a flattened and inverted T-shaped bone which lies in the median along the floor of cranium.

39. (c) 12 pair ribs are present in human beings, 1st to 7th pairs are called true ribs, 8th, 9th, 10th pairs are called false ribs, and last two pairs of ribs are called floating ribs.

41. (b) Number of bones in skull is 28

Bones of Cranium = 8
Facial bones = 14
Earossicles = 6
28

42. (a) The cranium is formed by 8 bones. (1 frontal bone, 2 parietal, 2 temporal, 1 occipital, 1 sphenoid, 1 ethmoid).

43. (c) The cranial segment is also cartilaginous in tadpole larva, but later, most of it changes into a tubular bone called sphenethmoid.

44. (a) It forms the main axis. It consists of skull – 22 bones, vertebral column – 33 vertebrae, sternum – 1 and ribs – 24.

46. (d) The dorsal, ventral and lateral part of thoracic basket are respectively formed of thoracic vertebrae, sternum, and ribs.

47. (d) Half of the vertebrate pelvic girdle consists of three bones ilium, ischium and pubis which fuse together in adult to be called innominate bone (hip bone).

48. (a) Hyoid bone is attached with the some muscles of the tongue and floor of the mouth.

50. (c) Cervical vertebrae are located in neck region.

53. (a) Human has 12 pairs of ribs, out of which first 7 pairs are called true or vertebrosternal ribs, next 3 pair are called false or vertebrochondral ribs and last 2 pairs are called floating or vertebral ribs.

Appendicular skeleton

1. (d) In rabbit, radius and ulna are separate bones but they are joined at both ends by ligaments.

2. (c) Glenoid cavity articulates humerus with scapula.

3. (c) Patella is the small bone in knee joint between femur and tibia. It is a sesamoid bone developed in the tendon of quadriceps femoris muscle.

4. (b) The protein present in the bone is known as ossein. Which activate the bone formation.

5. (c) Each upper arm or brachium of mammals also has a single long humerus bone whose swollen, spherical, and smooth proximal end or "head" fits into a glenoid cavity of the pectoral girdle on its side.

8. (a) All mature cartilages are surrounded by a firmly attached, dense fibrous sheath of connective tissue, called perichondrium.

9. (a) The labelled parts are a – Clavicle, b – Scapula, c – Humerus and d – Ulna* (Wrongly given as Radius).

11. (d) Humerus is the bone of upper arm. It articulates with ulna of fore arm. Two depression just above trochlea on anterior aspect are coronoid fossa and radial fossa respectively receives coronoid process of ulna and head of radius. One large depression on the posterior aspect is olecranon fossa receives olecranon process of ulna in extention of elbow.

12. (c) Synsacrum is the thoracic region of vertebral column in fowl. It consist of about 16 fused vertebrae and provide support to ilia bones of immense pelvic girdle.

13. (a) Synsacrum is a composite bone in birds which consists of about 16 fused vertebrae of different regions.

17. (b) Appendicular skeleton is situated at the lateral sides which actually extend outwards from the principal axis. It consists of pectoral and pelvic girdle and bones of arms and legs.

18. (a) A bone kept in *KOH* remain unaffected, only the surrounding muscles and connective tissue get dissolved, so that the bone now appears clean.

20. (b) Human skeleton is mainly formed of bones and cartilages. It is formed of 206 bones in adult man.

21. (a) Each hind limb contains 30 bones namely femur in thigh, patella in the knee, tibia and fibula in the lower leg, 7 tarsals in the ankle, 5 meta–tarsals in the sole and 14 phalanges in toes.

25. (a) Within the matrix of the compact bone of the shaft of long mammalian bones. (like humerus, femur, tibia), a network of branching canals (called haversian canals) is present in which lie the blood vessels.

27. (a) Ends of long bones are covered with cartilage. Ends of long bones takes part in forming the joint so the ends are covered by hyaline cartilage (articular cartilage).

28. (a) Ulna is produced into an olecranon process, to articulate into olecranon fossa and trochlea of humerus by a hinge joint.

29. (a) Each leg of cockroach is consist of five segments *i.e.*, basal flat coxa, a small trochanter a long femur, a slender spiny tibia, and the foot tarsus.

31. (b) Astragalus and calcaneum are the bones of hind limb.

32. (d) Humerus is differentiated into three parts head, shaft and lower end. Shaft has a *V*-shaped deltoid ridge, at its middle.

33. (a) Pelvic girdle comprises of the usual three bones ilium, ischium and pubis which are fused together into a single innominate or hip bone

35. (d) The ulna is thicker and longer, which bears a subterminal cup like receptacle called sigmoid notch or olecranon notch, for articulation with the distal end of humerus.

36. (c) The clavicle and interclavicle form a *V*–shaped furcula or wish bone or merrythought in birds.

38. (a) Ankle, also called tarsus, has 6 bones, called tarsals, arrangend in three rows having gliding joints, proximal row is with two bones. Outer calcaneum (heel bone) and inner talus.

40. (d) The ventral part of each half of pectoral girdle is comprise three skeletal pieces scapula, supra scapula, and coracoid.

41. (b) Hip bone is formed by the fusion of three bones; ilium on upper side, pubis on inner side and ischium below the pubis.

42. (c) Haversian canals are present in long bones such as humerus, femur, tibia etc.

43. (c) 1 humerus, 1 radius, 1 ulna, 8 carpal bones, 5 metacarpal bones, 5 digits (14 phalanges) phalangeal formula 2,3,3,3,3.

44. (c) Ulna projects beyond the radius as an olecranon process which has a deep sub terminal sigmoid notch for articulation with the distal end of humerus.

Joints

1. (a) An example of gliding joint is zygapophysis of adjacent vertebrae.

2. (c) Movable joints are called synovial joints. Which is found between humerus and ulna.

5. (c) The elbow joint.

8. (d) Shoulder and hip joints are the examples of ball and socket joints.

10 (b) Hyaline cartilage forms the articular surfaces at the joints of long bones where it is called as Articular cartilage.

14. (b) A gliding joint is the simplest of the synovial joints. Gliding joints are found between the carpal bones and between the tarsal bones.

17. (b) Hip joint (a type of ball and socket joint) found between head of femur and acetabulum of pelvic girdle.

18. (d) Achilles tendon is the strongest and thickest tendon in the body. Former is a large tendon at lower end of the gastrocnemius muscle, inserted into oscalcis.

20. (a) Ligments connects the two bones together and acts as a shock absorber to cushion when tibia and femur came together.

21. (c) Ligaments are the tissues which join the ends of bones together.

24. (b) Articular ends of both bones are either flat or slightly curved. To allow gliding or sliding movements as between zygopophysis of vertebrae.

25. (c) Tendon is a tough non-elastic connective tissue that joins a muscle to a bone. It is consists of collagen fibres.

Muscles

1. (c) Sarcolemma is present on the outside of skeletal muscle fibre. In the region of attachment, the sarcolemma is folded to form finger like projections.

2. (a) Fascia, actually is a sheet of connective tissue which covers the muscle.

8. (c) It is the principal calf muscle in the leg of a tetrapod. It arises by two heads connected to condyles of the femur. At its lower end it has a strong tendon which joins with that of the soleus muscle to form the tendon Achilles. Its main action is to provide the propelling force for walking and running.

UNIVERSAL BOOK DEPOT 1960

9. (a) Myosin protein forms anisotropic band and its centres forms 'M' line i.e. muscle fibre itself consists of myosin filaments. The cross bridges present in myosin molecules are enzymatic in nature and always tends towards, the centre of myosin filament thus causes the contraction of muscle fibre.

14. (c) During muscle fatigue due to deposition of lactic acid, cytoplasm becomes acidic thereby enzyme activity stops and food is not oxidised and as the energy is not available, muscular contraction stops.

16. (a) A-band has its middle a light zone called H-zone.

17. (d) There are about 639 types of muscles in human body which form about half of body weight.

18. (b) Myosin filaments are thicker and confined to the A-bands only. They are composed of myosin protein.

22. (b) In Cori's cycle large glycogen is broken down to lactic acid by glycolysis and energy is liberated. Some energy is used for regeneration of creatine phosphate and also for conversion of $4/5^{th}$ of lactic acid back to glycogen. The remaining $1/5^{th}$ of lactic acid is broken to CO_2 and H_2O.

23. (d) During muscle contraction, myosin and actin form cross bridges. This complex is known as actomyosin complex.

24. (a) Biceps is flexor muscle, it is attached with humerus and radius bone through tendon. Biceps bends or flexes arm at elbow.

25. (d) Red muscles have large number of mitochondria which can utilize more stored oxygen thereby producing more ATP so are termed as aerobic muscles.

26. (b) They help in accomodation of lens.

29. (d) It helps in adduction, extension and medial rotation of the shoulder as in swimming, rowing, climbing, pulling, folding the arm behind back and scratching the opposite scapula. It also helps in violent expiratory efforts as coughing, sneezing, etc.

Critical Thinking Questions

1. (d) In aquatic mammals (sirenia) cervical vertebrae are fused into a solid bony mass because of reduced neck in the manatees (sea caw) there are six cervical vertebrae only and the neural arches are sometimes incomplete.

5. (d) Squamosal is the posteriormost bone of the ramus. A zygomatic process extends forwards from its outer part.

7. (a) Epiphyseal plate (hyaline cartilage) is formed between diaphysis and epiphysis. This contributes in bone elongation.

8. (a) The greater trochanter and lesser trochanter are projections that serve as points of attachment for the tendons of some of the thigh and buttock muscles.

10. (d) Haversian canals are the characteristic features of bone.

11. (d) In birds, the fore limbs are modified to form wings.

12. (b) Hinge joints are found in the knee, elbow, ankle and interphalangeal joints. Thus interphalangeal joints are also called hinge joints.

13. (d) The excess ATP is used to synthesize creatine phosphate, an energy rich molecule that is found in muscle fibres.

14. (d) The stapedius muscle, which is innervated by the facial nerve (cranial nerve VII), is the smallest of all skeletal muscles.

Assertion and Reason

1. (b) Synovial fluid is a thick sticky fluid of egg white consistency, secreted by synovial membranes into the synovial cavity. Though the presence of synovial fluid is one of the reasons behind the mobility of the joints, but the most accurate reason is the arrangement of the bones at the joint, the spheroidal ball-like end of one bone articulates here with the cup-shaped depression in another. This allows the bone with the ball head to be moved freely in many planes. Shoulder joints and hip joints are the ball-and-socket joints.

2. (a) As muscle fibres are lacking in *Hydra*, the animal uses two types of contractile cells for this purpose. Processes of these cells run in the body wall both along the long axis of the body and arround the central body cavity. Contraction and relaxation of these cells respectively, shorten and elongate these processes. They consequently cause all types of movement of *Hydra* including shortening, elongation and also bending of body and tentacular movement. Locomotion is carried out by somersaults looping.

3. (c) Movements are produced at joints by contraction of skeletal muscles inserted into articulating bones. The contraction of an extensor muscle extends a joint, hence causing extension of the limb. Contraction of triceps brings about the extension of forearm at the elbow joint hence it is said to be the extensor muscle for elbow joint.

4. (c) The muscle fibre always contracts with the maximum force and this force doesn't rise on increasing the strength of the stimulus. If the stimulus is of strength below the threshold, then the muscle fibre doesn't contract at all. This is known as All or None law. But the entire muscle doesn't obey this law, it means that force of contraction of muscle increase with rise in strength of the stimulus. This is due to the fact that the strength of the threshold stimulus varies from muscle fibre to muscle fibre in a muscle.

Locomotion and Movement

SET Self Evaluation Test

1. The smooth sustained contraction of a muscle due to fusion of many twitches is called
   (a) Tendon (b) Tetanus
   (c) Twitch (d) Rigor mortis

2. Bucket–handle movements is seen in **[WB JEE 2010]**
   (a) 1st rib (b) 3rd rib to 5th rib
   (c) 6th rib to 10th rib (d) 11th and 12th rib

3. The characteristics and an example of a synovial joint in humans is **[MP PMT 2011; NEET 2013]**

	Characteristics	Examples
(a)	Lymph filled between two bones, limited movement	Gliding joint between carpals
(b)	Fluid cartilage between two bones, limited movements	Knee joint
(c)	Fluid filled between two joints, provides cushion	Skull bones
(d)	Fluid filled synovial cavity between two bones	Joint between atlas and axis

4. Pick out the correct match **[AIIMS 2009]**
   (a) Sternum – 14 (b) Pelvis – 3
   (c) Ribs – 20 (d) Face – 5

5. The cranium is formed of 8 bones. They are
   (a) 1 frontal, 2 parietals, 1 occipital, 2 temporals, 1 sphenoid and 1 ethmoid
   (b) 1 frontal, 1 parietal, 2 occipitals, 1 temporal, 2 sphenoids and 1 ethmoid
   (c) 2 frontals, 1 parietal, 1 occipital, 2 temporals, 1 sphenoid and 1 ethmoid
   (d) None of the above

6. The muscles associated with the heart of insects are **[Pb. PMT 1999]**
   (a) Alary (b) Radial
   (c) Striped (d) Pericardial

7. Which of the following bones are cartilaginous **[CPMT 1999; JIPMER 2001]**
   (a) Exoccipital and frontoparietal
   (b) Exoccipital and spenethmoid
   (c) Exoccipital and parasphenoid
   (d) Frontoparietal only

8. Intercalated discs are found in **[MP PMT 1993, 2000]**
   (a) Tendons (b) Striped muscles
   (c) Unstriped muscles (d) Cardiac muscles

9. Biceps and Triceps surround **[CPMT 1999; MP PMT 2001]**
   (a) Radius (b) Ulna
   (c) Humerus (d) Femur

10. A cotyloid bone is found in
    (a) Pelvic girdle of frog (b) Pelvic girdle of rabbit
    (c) Pectoral girdle of rabbit (d) Skull of frog

11. Fabellae bones are associated with **[MP PMT 2002]**
    (a) Angular joint (b) Elbow joint
    (c) Knee joint (d) Neck joint

12. Which of the following structure joins biceps muscles with radius-ulna **[CPMT 1995]**

    Or

    Humerus and muscles are connected with **[CPMT 1993]**
    (a) Tendon (b) Small muscles
    (c) Ligament (d) None of the above

13. Sometimes the muscles do not relax and become stiff. This condition is known as Rigor Mortis which is due to fall of concentration of
    (a) Myosin (b) Relaxin
    (c) Actin (d) ATP

AS Answers and Solutions

1	b	2	c	3	d	4	b	5	a
6	a	7	b	8	d	9	c	10	b
11	c	12	a	13	d				

12. (a) Tendon is very dense, strong fibrous connective tissue made of collagen fibres, which connects a skeletal muscle to a bone.

***